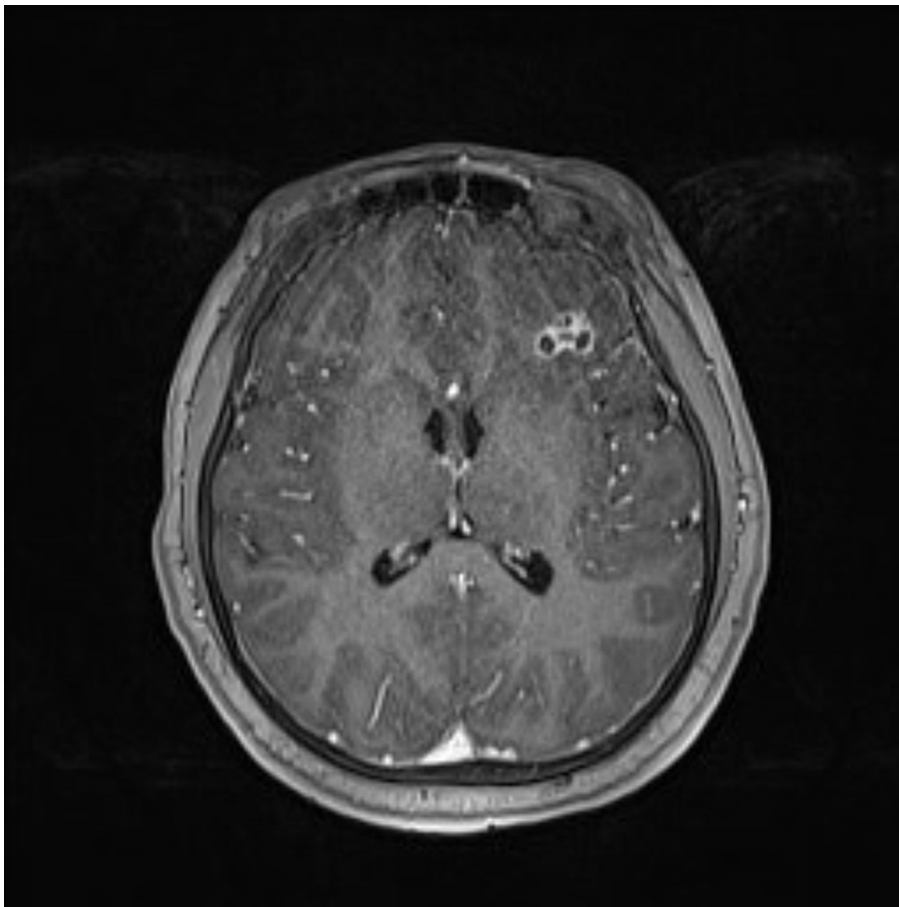


Disseminated *Echinococcus multilocularis* Infection without Liver Involvement in Child, Canada, 2018

Appendix



Appendix Figure. Brain MRI of child with disseminated *Echinococcus multilocularis* infection, axial T1 postcontrast image. There is a cluster of small ring-enhancing cavities within the left frontal lobe, surrounded by vasogenic edema.