

shopping space, and floor 7 contains shopping and office space. We created an illustration showing the floors where the eventual COVID-19 case-patients worked or shopped, along with dates of symptom onset, potential incubation periods, symptom durations, confirmed times of positive diagnosis, and times of discharge (Figure 1, panel A).

Except for those who had been on floor 7, all other case-patients denied direct close contact with other case-patients. The possibility of customers being infected from other sources cannot be excluded. However, most customers reported early symptom onset in a concentrated time frame (Figure 1, panel B). We found no convincing evidence of definitive transmission pathways in this building. Patients A–G (Figure 1, panel A) worked in the same room on floor 7. Other case-patients who had been on other floors denied any direct contact with confirmed patients from floor 7, but they shared common building facilities (e.g., restrooms, elevators). Also, staff from floor 7 visited shops on other floors daily.

Until now, no evidence has shown that SARS-CoV-2 can survive outside the body for long. However, Middle East respiratory syndrome coronavirus demonstrates high robustness and a strong capability to survive outside the body and can remain infectious for up to 60 minutes after aerosolization (4). Hence, the rapid spread of SARS-CoV-2 in our study could have resulted from spread via fomites (e.g., elevator buttons or restroom taps) or virus aerosolization in a confined public space (e.g., restrooms or elevators). All case-patients other than those on floor 7 were female, including a restroom cleaner, so common restroom use could have been the infection source. For case-patients who were customers in the shopping mall but did not report using the restroom, the source of infection could have been the elevators. The Guangzhou Center for Disease Control and Prevention detected the nucleic acid of SARS-CoV-2 on a doorknob at a patient's house (5), but Wenzhou Center for Disease Control and Prevention test results for an environmental sample from the surface of a mall elevator wall and button were negative.

We cannot exclude the possibility of unknown infected persons (e.g., asymptomatic carriers) spreading

the virus. However, according to screening protocols implemented by the Wenzhou Center for Disease Control and Prevention, we traced all close contacts and included all patients with positive PCR results, including the asymptomatic carrier (patient A), in this study. Our findings appear to indicate that low intensity transmission occurred without prolonged close contact in this mall; that is, the virus spread by indirect transmission.

The work was supported by Major Project of Wenzhou Municipal Science and Technology Bureau (ZY202004).

About the Author

Dr. Cai is deputy chief physician and deputy director of the comprehensive internal medicine department. Her major research interest focuses on infectious diseases and gastrointestinal diseases.

References

1. National Microbiology Data Center. Novel Coronavirus National Science and Technology Resource Service System [cited 2020 Jan 30]. <http://nmcdc.cn/nCoV>
2. Bai Y, Yao L, Wei T, Tian F, Jin DY, Chen L, et al. Presumed asymptomatic carrier transmission of COVID-19. *JAMA*. 2020 Feb 21 [Epub ahead of print]. <https://doi.org/10.1001/jama.2020.2565>
3. Rothe C, Schunk M, Sothmann P, Bretzel G, Froeschl G, Wallrauch C, et al. Transmission of 2019-nCoV Infection from an asymptomatic contact in Germany. *N Engl J Med*. 2020;382:970–1. <https://doi.org/10.1056/NEJMc2001468>
4. Pyankov OV, Bodnev SA, Pyankova OG, Agranovski IE. Survival of aerosolized coronavirus in the ambient air. *Journal of Aerosol Science*. 2018;115:158–63.
5. Meiping G. Coronavirus detected on doorknob in S. China's Guangzhou. 2020 [cited 2020 Feb 3]. <https://news.cgtn.com/news/2020-02-03/Coronavirus-detected-on-doorknob-in-S-China-s-Guangzhou-NMualLcOWY/index.html>

Address for correspondence: Guiqing He, Department of Infectious Diseases, Infectious Diseases Laboratory, Wenzhou Sixth People's Hospital, Wenzhou Central Hospital Medical Group, Wenzhou, 325000 China; email: hegq123@126.com; Jing Wu, Department of Infectious Diseases, #5-504, Huashan Hospital, Fudan University, 12 Wulumuqizhong Rd, Jing'an District Shanghai 200040, China; email: jingee@fudan.edu.cn

COVID-19 in 2 Persons with Mild Upper Respiratory Symptoms on a Cruise Ship, Japan

Takeshi Arashiro, Keiichi Furukawa, Akira Nakamura

Author affiliation: Asahi General Hospital, Chiba, Japan

DOI: <https://doi.org/10.3201/eid2606.200452>

We describe 2 cases of coronavirus disease in patients with mild upper respiratory symptoms. Both patients worked on a cruise ship quarantined off the coast of Japan. One patient had persistent, low-grade upper respiratory tract symptoms without fever. The other patient had rapid symptom cessation but persistent viral RNA detection.

Since December 2019, an outbreak of coronavirus disease (COVID-19) caused by severe acute respiratory syndrome coronavirus 2 (SARS-CoV-2) has been spreading globally (1). On January 25, 2020, a passenger disembarked a cruise ship in Hong Kong and on February 1 tested positive for SARS-CoV-2 (2). The ship docked in Yokohama, Japan, on February 3 for quarantine and isolation. On February 7, passengers and crew were provided thermometers and asked to check their temperature several times daily. Crew members were instructed to continue duties, report fever or respiratory symptoms, and follow quarantine instructions.

By February 28, a total of 705 COVID-19 cases were confirmed among 4,061 passengers and crew tested; 392 cases were asymptomatic, 36 persons were admitted to intensive care units, and 6 patients died (2). All case-patients from the ship were transferred to designated medical institutions in Japan (3).

Preliminary reports describe COVID-19 manifesting as pneumonia (4–6), but most cases are milder and could have more transmission potential because patients might not seek medical attention (7). Because of the lower threshold for testing persons on board, the cruise ship created an opportunity to observe mild COVID-19 cases and monitor patient symptoms. We describe 2 COVID-19 cases in persons with mild upper respiratory symptoms. The patients provided written, informed consent to share their clinical details.

Case 1 occurred in a 35-year-old woman from South Asia who worked as a restaurant server on the ship. On day 1 of her illness, February 7, she experienced throat dryness and a slight cough (Figure,

panel A). She and her roommate shared a bathroom with 2 others who had similar symptoms earlier. Case-patient 1 reported her symptoms but continued to work because she was afebrile. On day 3, she had throat soreness, stayed in her room, and was tested for SARS-CoV-2 by reverse transcription PCR (RT-PCR). On days 4–5, her symptoms diminished. On day 6, she was told she tested positive and was transferred to Asahi General Hospital (Chiba, Japan). At admission, she had a slight sore throat and cough. Her temperature was 36.5°C; blood pressure, 113/85 mm Hg; pulse, 92 bpm; respiration, 16 breaths/min; and oxygen saturation, 95% on ambient air. She had no underlying medical conditions and was taking no routine medication. On examination, her throat was bright red without exudates, lung auscultation was clear, and chest radiographs and blood tests were not clinically significant (Appendix Figure 1, panel A, Table 1, <http://wwwnc.cdc.gov/EID/article/26/6/20-0452-App1.pdf>). We did not suspect pneumonia and did not perform computed tomography. On day 8, she reported slight rhinorrhea. On day 9, RT-PCR again was positive for SARS-CoV-2. Her symptoms continued to diminish, and by day 10 she had discontinued all medications. RT-PCR results were positive on days 13 and 15, negative on day 19, positive again on day 20, and negative again on days 22 and 23, meeting the criteria for discharge, 2 consecutive negative assays. She never had fever, shortness of breath, or sputum, and daily lung auscultation was clear, suggesting absence of pneumonia.

Case 2 occurred in a 27-year-old man from South Asia who worked as a kitchen cleaner on the ship. On day 1 of his illness, February 8, he had a fever (38.6°C), sore throat, and cough. His roommate had similar symptoms that started 2 days before. Case-patient 2 reported his symptoms but continued to work. On day 2, he was tested for SARS-CoV-2 but continued to work. On day 3, his fever persisted, so he stayed in his room. By day 4, his symptoms resolved. On day 5, he was told he tested positive for SARS-CoV-2 and was transferred to Asahi General Hospital. At admission, he had no respiratory or other symptoms. He had no underlying medical conditions and was taking no routine medication. His temperature was 36.0°C; blood pressure, 132/85 mm Hg; pulse, 87 bpm; respirations, 16 breaths/min; and oxygen saturation, 95% on ambient air. On examination, his throat was bright red without exudates (Appendix Figure 2), lung auscultation was clear, and chest radiographs and blood tests were not clinically significant

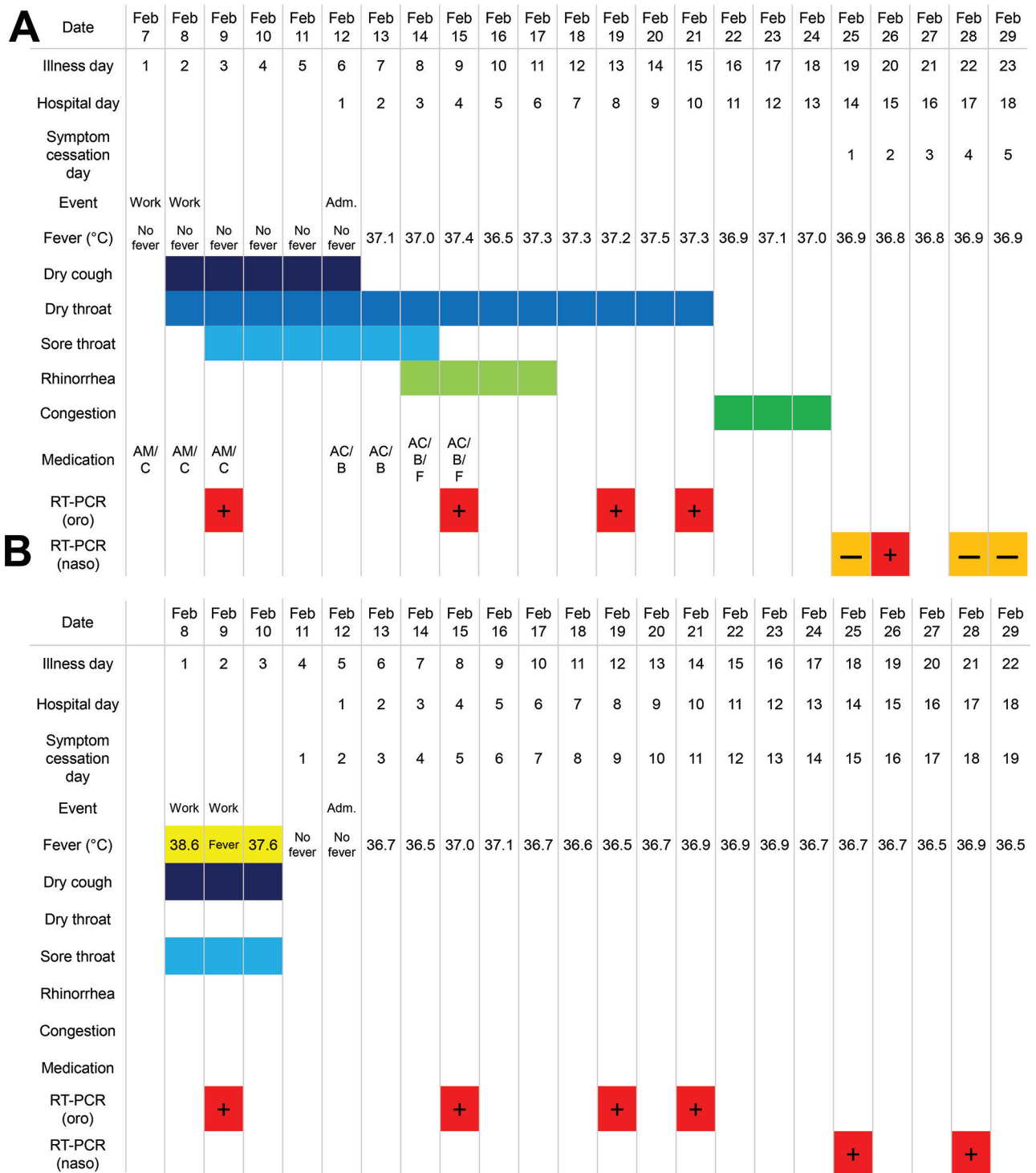


Figure. Clinical courses of 2 case-patients with coronavirus disease (COVID-19) admitted from a cruise ship docked in Japan, 2020. A) Case-patient 1, a 25-year-old woman who worked on the ship as a restaurant server. B) Case-patient 2, a 27-year-old man who worked on the ship as a kitchen cleaner. Acetaminophen was administered on an as-needed basis >2×/day after taking body temperature, so measured body temperature is not affected. Nasopharyngeal swabs were used after February 21, 2020, because a study by Zou et al. (10) suggested higher sensitivity of nasopharyngeal swab specimens over oropharyngeal swab specimens. AC, acetaminophen; Adm., admission; AM, amoxicillin; B, bakumondoto, a multiherb kampo medicine for dry cough; C, codeine-containing cough syrup; F, fexofenadine; naso, nasopharyngeal swab; oro, oropharyngeal swab; RT-PCR, reverse transcription PCR.

(Appendix Figure 1, panel B, Table 2). He remained asymptomatic, but on day 8, RT-PCR results were positive; results remained positive on days 12, 14, 18, and 21. His throat redness did not improve, but he did not report throat soreness or discomfort. He never experienced shortness of breath or sputum, and daily lung auscultations were clear.

We describe 2 mild cases of COVID-19 without discernable pneumonia, which could represent the clinical course in young, healthy persons. Worldwide, cases are appearing without apparent epidemiologic links (8). As the virus spreads, more mild COVID-19 cases are likely, and clinicians should be aware of clinical manifestations in the absence of severe symptoms. Case-patient 2's symptoms rapidly decreased, but detectable viral RNA persisted for >2 weeks. As of February 27, patients in Japan must have 2 consecutive negative RT-PCR results before they can be discharged (9). Viral RNA detection does not necessarily indicate infectivity, so we urgently need guidance for detection and management of mild COVID-19 to prepare for a possible pandemic and avoid overwhelming healthcare systems.

Acknowledgments

We thank the staff of the Kaiso Public Health Center and Chiba Prefectural Public Health Institute for public health support and testing, Ashley Stucky for thoughtful review of the manuscript, and Yuzo Arima and Takahiro Asami for intellectual discussion. We also thank the quarantine officers, cruise ship company, and healthcare personnel involved in the COVID-19 outbreak globally for their selfless dedication.

Addendum

As of April 6, a total of 712 coronavirus disease cases had been confirmed among 3,711 passengers and crew of the cruise ship (19.2%) (https://www.mhlw.go.jp/stf/houdou/houdou_list_202004.html). At the time of testing, 410 (57.6%) were asymptomatic; of those, 79 (11.1%) had symptoms develop within the 14-day self-monitoring period, leaving 331 persons who tested positive and remained asymptomatic after the self-monitoring period (46.5% of all cases). Forty (5.6%) patients were admitted to intensive care units (ICUs); 12 patients died (1.7%), including 1 person reported by the government of Australia to have died after transferring home. Of the cases we reported, case-patient 2 remained asymptomatic; RT-PCR results were negative on day 24, positive again on day 25, and negative again on days 27 and 28, meeting the criteria for discharge. His throat redness had improved by discharge. By March 27, both patients had been sent back to their home country

by air and instructed to self-isolate at home for an additional 14 days.

About the Author

Dr. Arashiro is a junior resident at Asahi General Hospital in Chiba, Japan, and a collaborating researcher with the Infectious Diseases Surveillance Center in the National Institute of Infectious Diseases, Tokyo, Japan. His research interests include infectious disease epidemiology and global health.

References

1. World Health Organization. Coronavirus disease (COVID-19) outbreak, 2020 [cited 2020 Feb 26]. <https://www.who.int/emergencies/diseases/novel-coronavirus-2019>
2. Ministry of Health, Labour and Welfare, Japan. Regarding COVID-19 cases on a cruise ship, 2020 Feb 26 [in Japanese] [cited 2020 Feb 26]. https://www.mhlw.go.jp/stf/houdou/houdou_list_202002.html
3. Ministry of Health, Labour and Welfare, Japan. Cabinet order to designate novel coronavirus infection 2019 as designated infectious disease, 2020 Jan 28 [in Japanese] [cited 2020 Feb 26]. <https://www.mhlw.go.jp/content/10900000/000589747.pdf>
4. Huang C, Wang Y, Li X, Ren L, Zhao J, Hu Y, et al. Clinical features of patients infected with 2019 novel coronavirus in Wuhan, China. *Lancet*. 2020;395:497–506. [https://doi.org/10.1016/S0140-6736\(20\)30183-5](https://doi.org/10.1016/S0140-6736(20)30183-5)
5. Chen N, Zhou M, Dong X, Qu J, Gong F, Han Y, et al. Epidemiological and clinical characteristics of 99 cases of 2019 novel coronavirus pneumonia in Wuhan, China: a descriptive study. *Lancet*. 2020;395:507–13. [https://doi.org/10.1016/S0140-6736\(20\)30211-7](https://doi.org/10.1016/S0140-6736(20)30211-7)
6. Chang D, Lin M, Wei L, Xie L, Zhu G, Dela Cruz CS, et al. Epidemiologic and clinical characteristics of novel coronavirus infections involving 13 patients outside Wuhan, China. *JAMA*. 2020 Feb 7 [Epub ahead of print]. <https://doi.org/10.1001/jama.2020.1623>
7. Munster VJ, Koopmans M, van Doremalen N, van Riel D, de Wit E. A novel coronavirus emerging in China—key questions for impact assessment. *N Engl J Med*. 2020;382:692–4. <https://doi.org/10.1056/NEJMp2000929>
8. World Health Organization. Emergency ministerial meeting on COVID-19 organized by the African Union and the Africa Centres for Disease Control and Prevention, 2020 Feb 22 [cited 2020 Feb 26]. <https://www.who.int/dg/speeches/detail/emergency-ministerial-meeting-on-covid-19-organized-by-the-african-union-and-the-africa-centres-for-disease-control-and-prevention>
9. Ministry of Health, Labour and Welfare, Japan. Discharge criteria for COVID-19 patients, 2020 Feb 18 [in Japanese] [cited 2020 Feb 26]. <https://www.mhlw.go.jp/content/10900000/000597947.pdf>
10. Zou L, Ruan F, Huang M, Liang L, Huang H, Hong Z, et al. SARS-CoV-2 viral load in upper respiratory specimens of infected patients. *N Engl J Med*. 2020 Feb 19 [Epub ahead of print]. <https://doi.org/10.1056/NEJMc2001737>

Address for correspondence: Takeshi Arashiro, Asahi General Hospital, 1 1326, Asahi City, Chiba 289-2511, Japan; email: arash003@umn.edu