



Published in final edited form as:

*Graefes Arch Clin Exp Ophthalmol.* 2018 November ; 256(11): 2035–2040. doi:10.1007/s00417-018-4093-7.

## INNER RETINAL THICKENING IN NEWLY DIAGNOSED CHOROIDAL NEOVASCULARIZATION

Ilkay Kilic Muftuoglu, MD<sup>1,2</sup>, Tiezhu Lin, MD<sup>1</sup>, William R. Freeman, MD<sup>1,\*</sup>

<sup>1</sup>Department of Ophthalmology, Jacobs Retina Center, Shiley Eye Institute, University of California San Diego, CA, US

<sup>2</sup>Also affiliated with Department of Ophthalmology, Istanbul Training and Research Hospital, Istanbul, Turkey

### Abstract

**Purpose:** Automated segmentation of retinal layers by spectral-domain optical coherence tomography (SD-OCT) is usually erroneous in the presence of retinal diseases. The purpose of this study is to report the changes in ganglion cell complex (GCC) comprising retina nerve fiber layer (RNFL), ganglion cell layer (GCL), and inner plexiform layer (IPL) in neovascular age-related macular degeneration (AMD) patients by manually correcting the automated segmentation errors.

**Methods:** Thirty-eyes of 30 patients with new-onset choroidal neovascularization secondary to neovascular AMD and 30 eyes of 30 healthy subjects were included. The inner retinal thicknesses were measured using early treatment diabetic retinopathy circle in the central 1 millimeter (mm) (fovea) and surrounding 3 mm diameter (parafovea) after checking the accuracy of automated segmentation lines. Manual segmentation was done to ensure the accurate segmentation, when needed.

**Results:** Neovascular AMD patients had thicker mean RNFL, GCL, IPL and GCC thicknesses within the fovea compared to healthy eyes ( $p=0.04$ ,  $p=0.001$ ,  $p=0.032$  and  $p=0.005$ , respectively). In the parafoveal area, among the thickness related measurements, the only significant difference was a thicker mean RNFL ( $p=0.002$ ).

**Conclusion:** Diffuse thickening of inner retinal layers in neovascular AMD may overestimate actual GCC thickness within fovea. This pseudo-increase in GCC thickness and inner retinal layers in general likely does not reflect more cells or tissue, but rather diffuse edema which leads to a falsely increased reading of layer thickness. Such false readings may also make the

---

\*Corresponding author: William R. Freeman, MD, Address: University of California San Diego, Jacobs Retina Center, Shiley Eye Institute, 9415, Campus Point Drive, La Jolla, CA 92037, wrfreeman@ucsd.edu, Phone: (858) 534-3513.

**Conflict of Interest:** All authors certify that they have no affiliations with or involvement in any organization or entity with any financial interest (such as honoraria; educational grants; participation in speakers' bureaus; membership, employment, consultancies, stock ownership, or other equity interest; and expert testimony or patent-licensing arrangements), or non-financial interest (such as personal or professional relationships, affiliations, knowledge or beliefs) in the subject matter or materials discussed in this manuscript.

**Ethical approval:** All procedures performed in studies involving human participants were in accordance with the ethical standards of the institutional and/or national research committee and with the 1964 Helsinki declaration and its later amendments or comparable ethical standards.

assessment of other conditions that lead to reduced inner retinal layer thickness such as glaucoma, optic nerve disease or retinovascular occlusions more difficult.

### Keywords

ganglion cell layer; neovascular AMD; choroidal neovascularization; OCT; segmentation; ganglion cell complex; GCC

---

## INTRODUCTION

Neovascular age-related degeneration (nAMD), which is characterized by exudation, hemorrhage and eventually scarring, is the major cause of vision loss in industrialized countries [1]. Although photoreceptors have been considered to be the cells that are responsible for the majority of visual outcomes in exudative and non-exudative AMD patients, there have been some reports suggesting that inner retinal cells, particularly ganglion cells, may also be damaged by the AMD process, even in early stages of the disease [2,3].

Recent advances in spectral-domain optical coherence tomography (SD-OCT) software allow clinicians to individually delineate retinal layers such as retinal nerve fiber layer (RNFL), ganglion cell layer (GGL), and inner plexiform layer (IPL) or to evaluate these layers in their entirety by combining readings into the so called ganglion cell complex (GCC) [4,5]. This has been found to be useful in glaucoma evaluation. Prior small studies evaluating GCC thickness in new onset nAMD patients [6,7], suggested that GCC thickness was lower or remain unchanged compared to healthy eyes. However, these studies used only automated segmentation algorithms which, in our experience, may fail to accurately delineate retinal layers and lead over- or underestimation of retinal layer thickness [2,3,4,8]. Therefore, in order to clarify the effect of choroidal neovascularization (CNV) on inner retinal layer thickness, we performed a larger study and performed manual correction of automated segmentation algorithms as needed. This may also help clarify if there is early inner retinal damage as a result of CNV which will be important for evaluation of future regenerative therapies of the retina [9,10]. In addition, subretinal prostheses are on the concept that functioning inner retinal layer cells such as bipolar cells or ganglion cells remain relatively intact, it is of interest to determine how these layers degenerate in eyes with new onset CNV. Also since GCC thickness is shown to be an important marker of glaucoma, glaucoma diagnosis or evaluation may be difficult in eyes with CNV.

## METHODS

Patients who were diagnosed with new-onset CNV due to nAMD and healthy subjects as a control group were included in the retrospective study. The University of California, San Diego Institutional Review Board approval was acquired for the review and analysis of patients' medical records. The study adhered to the tenets of the Declaration of Helsinki for research involving human subjects and complied with Health Insurance Portability and Accountability Act (HIPAA) regulations. The medical records of the healthy subjects were retrieved through a computer-base software which has been used to store the patients imaging records at our institution.

All patients underwent a thorough ophthalmological examination including best-corrected visual acuity (BCVA), measurement of intraocular pressure (IOP) by Goldmann applanation tonometry, slit-lamp biomicroscopy, dilated fundus examination through 90 D lens as well as multimodal imaging including SD-OCT and fundus fluorescein angiography (FA) using Spectralis (HRA2/ Spectralis acquisition module 6.3.2.0, Heidelberg Engineering, Heidelberg, Germany). All images were acquired by trained operators with the same device. Age at the time of presentation, lens status, presence of refractive error, ocular and systemic history were recorded from the medical charts. When 2 eyes of the same subject were eligible, one randomly selected eye of each subject was included in the study. Exclusion criteria included as follows: history of ocular surgery other than cataract surgery, presence of diabetes mellitus, presence of high refractive errors (spherical equivalent ranging from  $\pm 3$  Diopter), presence of any other retinal diseases likely affect the retinal layer thickness, eyes with a diagnosis of glaucoma or IOP  $>25$  mmHg and eyes with poor image quality.

Neovascular AMD patients were diagnosed clinically by the same experienced retina specialist (W.R.F.) and the diagnoses were confirmed by the multimodal imaging including SD-OCT and FA. Further classification was done based on the characteristics of the CNV lesion as type 1, type 2, type 3 or mixed type CNV.<sup>11</sup> Type 1 CNV was defined as fibrovascular pigment epithelial detachment with a stippled hyperfluorescence, or late leakage of undetermined source. Type 2 CNV was defined as the presence of CNV located above the retina pigment epithelium-Bruch's membrane complex and Type 3 neovascularization was identified on OCT by the presence of a characteristic intraretinal hyperreflective lesion within the outer nuclear layer and associated intraretinal edema with or without sub-RPE fluid, as described previously.<sup>11</sup> The CNV was regarded as subfoveal or extrafoveal when CNV activity with overlying IRF and/ or SRF was most pronounced within 1000 microns of fovea or somewhere within 3000 microns of the fovea (parafovea).

### SD-OCT Image Acquisition and Image Analysis

Macula volume cubes centered on the fovea consisting at least 37 B-scans with a minimum of 10 automated real time-repetition rate (ART) were obtained by using the same Spectralis device. Among the several consecutive images of the patients taken during follow-up, the very first image at the time of new-onset CNV diagnosis was reviewed. In each case, the auto-segmentation mode that automatically defined the inner and outer boundary of retinal layers was activated. Then, thickness maps for RNFL, GCL and IPL were evaluated for the potential segmentation errors. Segmentation error was regarded as the improper location of presentative lines in at least one cross-sectional images [8]. The inbuilt software defined the RNFL, GCL, IPL thickness as the distance between internal limiting membrane (ILM) and outer boundary of RNFL, the distance between outer boundary of RNFL and outer boundary of ganglion layers, and the distance between the outer boundary of ganglion cells and outer boundary of inner plexiform layer, respectively (Figure 1). Figure 2 shows the multimodal imaging in a patient with improper delineated retinal layers by automated segmentation using SD-OCT. When needed, manual adjustment was done starting from the innermost layer towards the outer retinal layers with paying attention to reflectivity of each layer. If the software was not able to draw the borders of each layers, boundary lines were manually drawn using caliper function of the software. Then, accurate thicknesses of given retinal

layers were recorded in macular subfields that were determined by early treatment diabetic retinopathy study (ETDRS) circle with a 1 mm diameter inner diameter and 3 mm diameter outer diameter as follows: mean, superior, temporal, inferior and nasal quadrants. All images were analyzed by 2 experienced retina specialists who were masked to their image analysis and patient's demographics using the same computer display and monitor settings.

### Statistical Analysis

The normality of the variables was checked using Kolmogorov-Smirnov test. The agreement between the thickness of given layers among the 2 graders was evaluated using intraclass correlation (ICC) and ICC was found to be perfect (ICC=0.872) between the 2 graders for GCC thickness. Mann-Whitney-U test was used to show if there was any significant difference in any continuous variables between the 2 groups (CNV versus control group), whereas chi-square test was used for comparison of categorical variables. Best corrected visual acuities were converted to logMAR (Logarithm of the Minimum Angle of Resolution) for the statistical analysis. All analyses were carried out using SPSS, version 24 (SPSS Inc, Chicago, US). A two-sided p value less than 0.05 was considered statistically significant.

## RESULTS

Thirty eyes of 30 consecutive CNV patients meeting the inclusion criteria and 30 eyes of 30 age matched healthy subjects were included the study. The baseline demographics of the study population are summarized in Table 1. There were no significant differences in mean age, spherical equivalent, IOP, or SD-OCT strengths between the 2 groups. All eyes in CNV group (100%) and 28 eyes (93.33%) from the control subjects did require manual correction of segmentation in at least one SD-OCT scan.

The data for the distribution of CNV types revealed that type 1 CNV was the most common CNV type (14/30) (46.66%), followed by type 2 CNV (9/30) (33.33%) and type 3 CNV (4/30) (13.33%) CNV. Ten-percent of eyes (3/30) had mixed type CNV. Most of the nAMD patients (21/30) (70%) had extrafoveal (within 3000 microns of fovea) CNV. SD-OCT characteristics of the eyes with neovascular AMD are illustrated in table 2. Quantitative measurements of the macular inner retinal thicknesses are given in table 3. The mean CMT was  $414.54 \pm 120.22$  microns ( $\mu\text{m}$ ) (range: 260–765  $\mu\text{m}$ ) in nAMD group and  $277 \pm 19.29$   $\mu\text{m}$  (range: 233–312  $\mu\text{m}$ ) in the control group; CNV eyes had significantly thicker retina than the controls ( $p < 0.001$ ).

The mean GCC thickness within the fovea was significantly higher in CNV eyes ( $p = 0.005$ ) ( $57.09 \pm 11.51$   $\mu\text{m}$  in CNV eyes and  $48.55 \pm 7.1$   $\mu\text{m}$  in the control group). When looking at the individual inner retinal layers, the mean RNFL thickness ( $15.00 \pm 4.1$   $\mu\text{m}$  in CNV eyes and  $12.8 \pm 1.8$   $\mu\text{m}$  in the control group), the mean GCL thickness ( $18.86 \pm 4.7$   $\mu\text{m}$  in CNV eyes and  $14.7 \pm 0.54$   $\mu\text{m}$  in the control group) and the mean IPL thickness ( $23.22 \pm 5.58$  in CNV group and  $20.92 \pm 2.92$   $\mu\text{m}$  in the control group) thicknesses within central 1mm macular area were all found to be thicker in nAMD group compared to controls ( $p = 0.04$ ,  $p = 0.001$ , and  $p = 0.032$ , respectively). Though there was a trend toward increase in all inner retinal layer thicknesses in nAMD eyes in the parafovea, only the difference in mean parafoveal RNFL thickness between the 2 groups reached the statistically significant level ( $p = 0.002$ ).

## DISCUSSION

Neovascular age-related macular degeneration is a disease which mainly effects the outer retinal layers.<sup>12</sup> Despite the presence of a few studies looking at the inner retinal layers such as RNFL and GCL and showing that these layers can also be involved to disease process [6,7], these reports are limited to automated segmentation of retinal layers by SD-OCT. We have previously shown that automated segmentation must be corrected in eyes with AMD in order to properly evaluate inner retinal structures as the segmentation algorithms are often inaccurate when there is distortion of the anatomy. Although a decrease in the mean GCC thickness has been reported by our group in varying severity of dry AMD patients presumably due to trans synaptic degeneration [3,13], we now report that in treatment naïve neovascular AMD patients without geographic atrophy, there is a thicker mean RNFL, GGL, IPL and GCC thicknesses within fovea compared to healthy subjects. We believe this may be due to diffuse thickening from fluid or exudate from the subretinal or sub-RPE CNV and that this phenomenon needs to be understood when interpreting measurements of inner retinal thickness.

Since recent studies have shown that GCC thickness is a useful marker to differentiate glaucomatous eyes from healthy subjects, the increase in GCC thickness in neovascular AMD patients [14,15], as we have found, may interfere with glaucoma diagnosis in eyes with some activity of CNV. In addition, future studies evaluating possible long term toxicity of drugs may incorporate measurements of inner retinal layer thickness and integrity. Based on our study, such measurements may result in suggestions of loss of inner retinal structure and toxicity that may not be real.

Our findings may explain why some have found loss of inner retinal structure after treatment with anti-vascular endothelial growth factor (anti-VEGF) drugs. In one longitudinal study comprising patients with nAMD, mean GCL thickness was found to be similar to the fellow eye of the same patient at baseline. Then, after having a mean of 31.5 anti-VEGF injections over 45 months follow-up, mean GCL thickness significantly decreased.<sup>7</sup> The authors suggested that this decrease may be explained with several mechanisms including reduced input from degenerated photoreceptors to the ganglion cells causing apoptosis, intraocular pressure spikes following anti-VEGF injections and lastly blockage of VEGF-A which acts as a survival factor for ganglion cells. The diffuse edema is not clinically visible when evaluating a given scan due to its subtle nature. Thus, previously reported decreases in GCL thickness with anti-VEGF therapy may be partially due to a decrease in retinal edema rather than a decrease in ganglion cell neurons. Therefore, clinicians should be aware of misleading retinal thickness measurements in CNV eyes. On the other hand, our findings of thickening in the inner retina were more prominent in the central 1 mm area than the central 3 mm macular area, likely because the smaller central area may be more effected by edema and also most of the eyes had extra foveolar CNV.

In histopathological studies [16], nAMD eyes with longstanding CNV do exhibit loss of inner retinal elements. However, this is likely a late effect and due to trans synaptic degeneration as this is seen in dry AMD as well.

There are some limitations to be mentioned in the study. One of these is the small sample size. However, we reviewed at least 37-scans for each retinal layers (37×3) of each eyes (roughly a total of 6660 B-scans) and corrected the segmentation error failures and our findings were statistically significant. Though our sample size does not permit us to analyze the differential needs for manual segmentation correction across types of CNV, this would be an interesting future study. Despite these limitations, our study is unique with the advantage of having carefully corrected segmentation lines.

In conclusion, in CNV eyes diffuse thickening of the inner retinal layers which is not obvious upon casual viewing of SD-OCT scans, may cause increased measured thickness of inner retinal layers. Such findings may interfere with glaucoma evaluation and also, when measured over the course of anti-VEGF therapy, may falsely lead to the conclusion that treatment for CNV causes loss in inner retinal tissue.

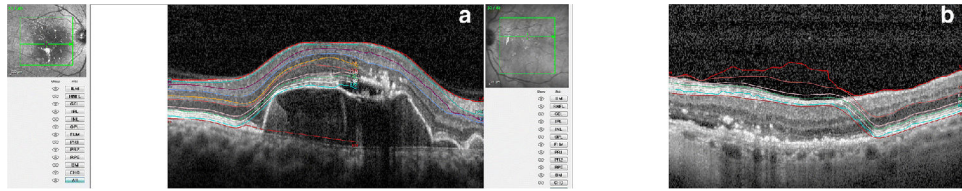
### Funding:

Supported in part by a core grant from the National Eye Institute P30 EY022589 (WRF) and an unrestricted grant from Research to Prevent Blindness, NY (WRF). The funding organizations had no role in the design or conduct of this research. The funding organizations had no role in the design or conduct of this research.

### REFERENCES

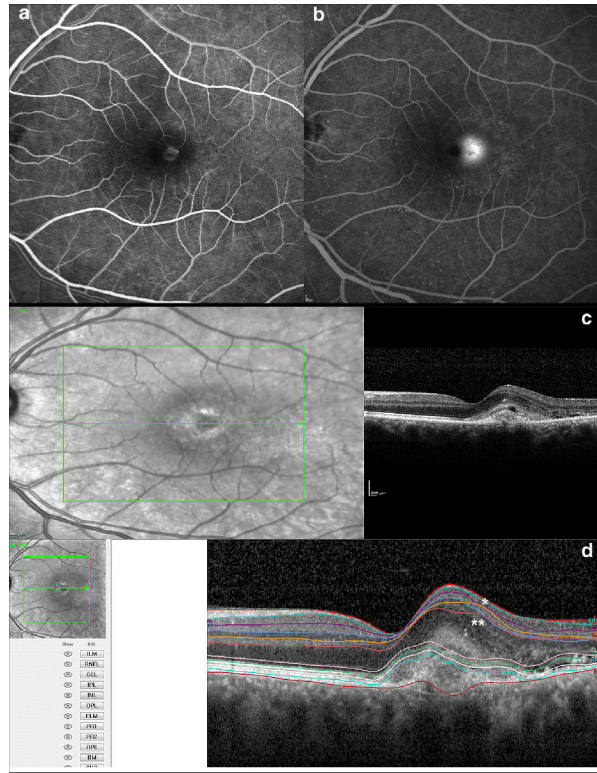
1. Wong WL, Su X, Li X, et al. (2014) Global prevalence of age-related macular degeneration and disease burden projection for 2020 and 2040: a systematic review and meta-analysis. *Lancet Glob Health* 2:106–116.
2. Savastano MC, Minnella AM, Tamburrino A, et al. (2014) Differential vulnerability of retinal layers to early age-related macular degeneration: evidence by SD-OCT segmentation analysis. *Invest Ophthalmol Vis Sci* 29:560–566.
3. Muftuoglu IK, Ramkumar HL, Bartsch DU, Meshi A, Gaber R, Freeman WR (2017) Quantitative analysis of the inner retinal layer thicknesses in age-related macular degeneration using corrected optical coherence tomography segmentation. *Retina* 6 23 Doi: 10.1097/iae.0000000000001759. [pub ahead of print]
4. Lee HJ, Kim MS, Jo YJ, Kim JY (2015) Ganglion Cell-Inner Plexiform Layer Thickness in Retinal Diseases: Repeatability Study of Spectral-Domain Optical Coherence Tomography. *Am J Ophthalmol* 160:283–289. [PubMed: 26004405]
5. Kim HJ, Lee SY, Park KH, et al. (2016) Glaucoma Diagnostic Ability of Layer-by-Layer Segmented Ganglion Cell Complex by Spectral-Domain Optical Coherence Tomography. *Invest Ophthalmol Vis Sci* 57:4799–4805. [PubMed: 27654408]
6. Zucchiatti I, Parodi MB, Pierro L, et al. (2015) Macular ganglion cell complex and retinal nerve fiber layer comparison in different stages of age-related macular degeneration. *Am J Ophthalmol* 160:602–607. [PubMed: 26052088]
7. Beck M, Munk MR, Ebnetter A, Wolf S, Zinkernagel MS (2016) Retinal Ganglion Cell Layer Change in Patients Treated With Anti-Vascular Endothelial Growth Factor for Neovascular Age-related Macular Degeneration. *Am J Ophthalmol* 167:10–7. [PubMed: 27084000]
8. Hwang YH, Kim MK, Kim DW (2016) Segmentation Errors in Macular Ganglion Cell Analysis as Determined by Optical Coherence Tomography. *Ophthalmology* 123:950–958. [PubMed: 26854040]
9. Schwartz SD, Tan G, Hosseini H, Nagiel A (2016) Subretinal Transplantation of Embryonic Stem Cell-Derived Retinal Pigment Epithelium for the Treatment of Macular Degeneration: An Assessment at 4 Years. *Invest Ophthalmol Vis Sci* 57:1–9. [PubMed: 26746012]

10. Eng JG, Agrawal RN, Tozer KR, et al. (2011) Morphometric analysis of optic nerves and retina from an end-stage retinitis pigmentosa patient with an implanted active epiretinal array. *Invest Ophthalmol Vis Sci* 52:4610–4616. [PubMed: 21296811]
11. Freund KB, Zweifel SA, Engelbert M (2010) Do we need a new classification for choroidal neovascularization in age-related macular degeneration? *Retina* 30:1333–1349. [PubMed: 20924258]
12. Kim YM, Kim JH, Koh HJ (2012) Improvement of photoreceptor integrity and associated visual outcome in neovascular age-related macular degeneration. *Am J Ophthalmol* 154:164–173. [PubMed: 22541932]
13. Ramkumar HL, Nguyen B, Bartsch DU, et al. (2017) Reduced Ganglion Cell Volume on Optical Coherence Tomography In Patients with Geographic Atrophy. *Retina*. 11 7 Doi: 10.1097/IAE.0000000000001867.
14. Hammel N, Belghith A, Weinreb RN, Medeiros FA, Mendoza N, Zangwill LM (2017) Comparing the Rates of Retinal Nerve Fiber Layer and Ganglion Cell-Inner Plexiform Layer Loss in Healthy Eyes and in Glaucoma Eyes. *Am J Ophthalmol* 178:38–50 [PubMed: 28315655]
15. Lee EK, Yu HG (2015) Ganglion Cell-Inner Plexiform Layer and Peripapillary Retinal Nerve Fiber Layer Thicknesses in Age-Related Macular Degeneration. *Invest Ophthalmol Vis Sci* 56:3976–3983. [PubMed: 26087362]
16. Medeiros NE, Curcio CA (2001) Preservation of ganglion cell layer neurons in age-related macular degeneration. *Invest Ophthalmol Vis Sci* 42:795–803. [PubMed: 11222543]



**Figure 1.** represents some spectral-domain optical coherence tomography segmentation errors seen on automated segmentation mode in 2 patients with choroidal neovascularization secondary to neovascular macular degeneration. Note discontinuity of segmentation lines of given retinal layers (Figure A) and improper delineation of retinal layers (B) by the automated mode.





**Figure 2.** shows the multimodal imaging including fluorescein angiography (A, B) and spectral-domain optical coherence tomography (SD-OCT) (C) of a patient with choroidal neovascularization (CNV) secondary to age-related macular degeneration. Leaking is seen the late phase of the angiogram (A) along with extrafoveal CNV extending to subfoveal area (B) on horizontal B-scan. On automated segmentation mode (D), improper segmentations of inner nuclear layer (\*) and outer plexiform layer (\*\*) are seen with some segmentation errors also in the outer retinal layers.

**Table 1.**

Demographics of the study population

	CNV Group	Control Group	P
<b>Number of patients</b>	30	30	
<b>Mean age<math>\pm</math>SD, year</b>	74.12 $\pm$ 9.80	73.13 $\pm$ 19.28	0.78
<b>Gender, female/male (n)</b>	12/18	10/20	0.32
<b>Spherical Equivalent, Diopter</b>	-0.25 $\pm$ 1.63	-0.10 $\pm$ 1.65	0.56
<b>Intraocular pressure, mean (mmHg)</b>	13.52 $\pm$ 2.14	14.0 $\pm$ 3.23	0.65
<b>BCVA, logMAR Snellen Equivalent</b>	0.1 $\pm$ 0.02 $\approx$ 20/25	0 20/20	<0.001
<b>Signal Strength of the SD-OCT scan reviewed</b>	66.0 $\pm$ 4.32	66.2 $\pm$ 7.63	0.98

CNV=choroidal neovascularization, SD=standard deviation, N=number, BCVA=best-corrected visual acuity, logMAR=Logarithm of the Minimum Angle of Resolution, SD=spectral-domain optical coherence tomography

Continuous parameters are presented as mean and standard deviation ( $\pm$ )

**Table 2.**

SD-OCT characteristic of the eyes with neovascular age-related macular degeneration

<b>Fluid type</b>	
Intraretinal fluid- only, n	7 (23.33%)
Subretinal fluid- only, n	14 (46.66%)
Intraretinal+subretinal fluid	9 (30.00%)
<b>Presence of PED, n</b>	25 (83.33%)
Fibrovascular, n	15 (60%)
Drusenoid, n	6 (24%)
Serous, n	4 (16%)

SD-OCT=spectral domain optical coherence tomography, n=number, PED=pigment epithelial detachment

Author Manuscript

Author Manuscript

Author Manuscript

Author Manuscript

**Table 3.**

Comparison of inner retinal layers thicknesses between treatment naïve choroidal neovascularization patients and healthy controls

	CNV Group	Control Group	P
<b>1 mm*</b>			
RNFL, $\mu\text{m}$	15.00 $\pm$ 4.1	12.8 $\pm$ 1.8	0.040
GGL, $\mu\text{m}$	18.86 $\pm$ 4.7	14.7 $\pm$ 0.54	0.001
IPL, $\mu\text{m}$	23.22 $\pm$ 5.58	20.92 $\pm$ 2.92	0.032
GCC, $\mu\text{m}$	57.09 $\pm$ 11.51	48.55 $\pm$ 7.1	0.005
<b>3 mm*</b>			
RNFL, $\mu\text{m}$	22.9 $\pm$ 4.09	19.8 $\pm$ 1.4	0.002
GGL, $\mu\text{m}$	40.9 $\pm$ 4.2	39.0 $\pm$ 5.11	0.062
IPL, $\mu\text{m}$	37.8 $\pm$ 4.7	36.7 $\pm$ 2.9	0.286
GCC, $\mu\text{m}$	99.85 $\pm$ 12.3	78.56 $\pm$ 7.94	0.880

$\mu\text{m}$ =micron, RNFL=Retinal nerve fiber layer; GCL=Ganglion cell layer; IPL=Inner plexiform layer; GCC=ganglion cell complex (comprised of the sum of the RNFL, GCL, and IPL), mm=milimeter

\* 1 mm and 3 mm refer to the Early Treatment Diabetic Retinopathy Study (ETDRS) circle diameter represented

All parameters are presented as mean and  $\pm$  standard deviation