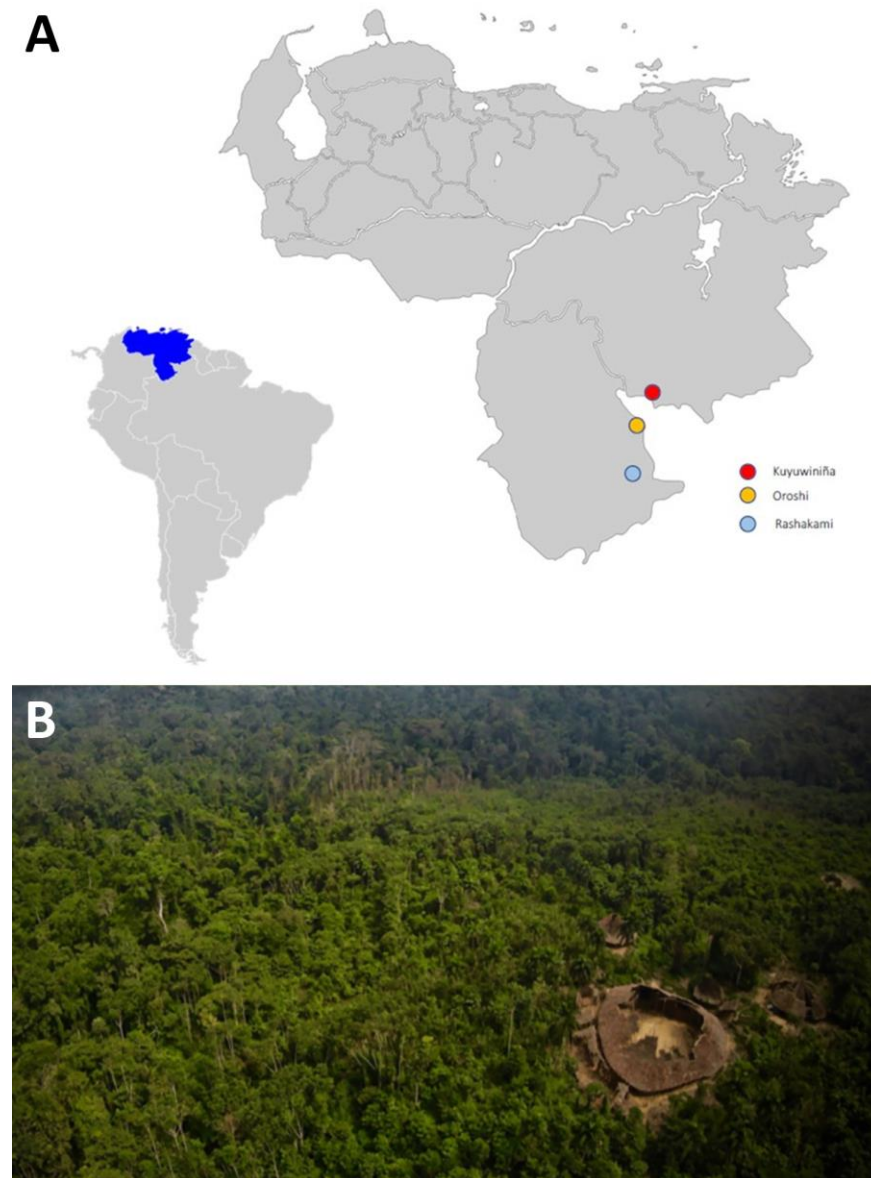
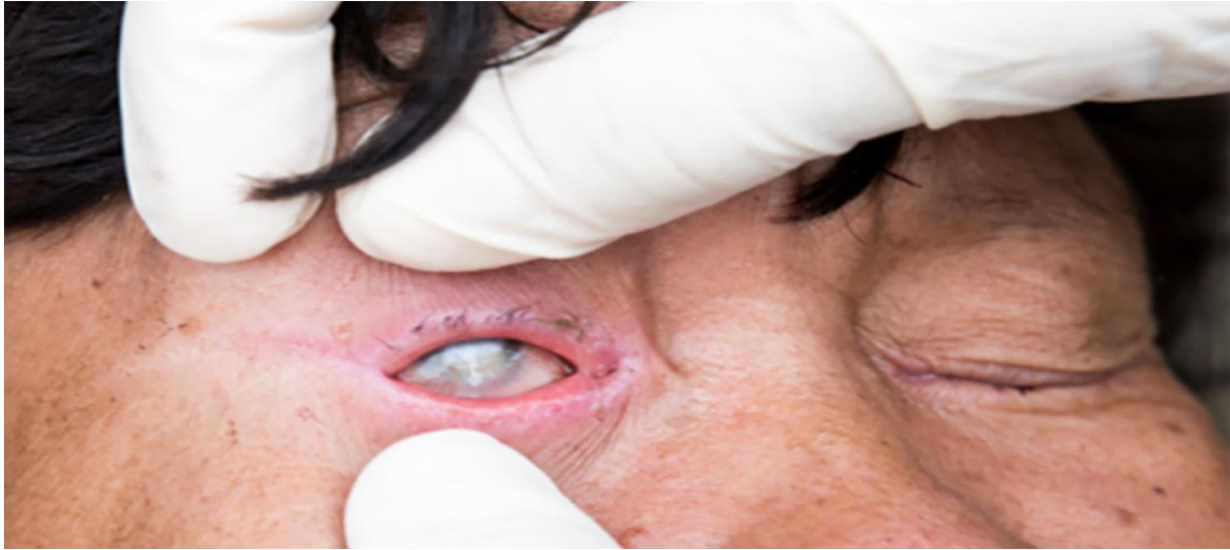

# Trachoma in 3 Amerindian Communities, Venezuelan Amazon, 2018

## Appendix



**Appendix Figure 1.** Study of trachoma in 3 Amerindian communities, Amazonian Venezuela, 2018. A) Location of study areas. B) Kuyuwiniña community, Alto Caura River basin, Bolivar.



**Appendix Figure 2.** Case-patient 2, a 35-year-old woman, with trachomatous trichiasis, madarosis, blepharitis, and conjunctivitis in both eyes; corneal opacity in the right eye; and full blindness in the left, Community Kuyuwiniña community. Alto Caura River basin, Bolivar.