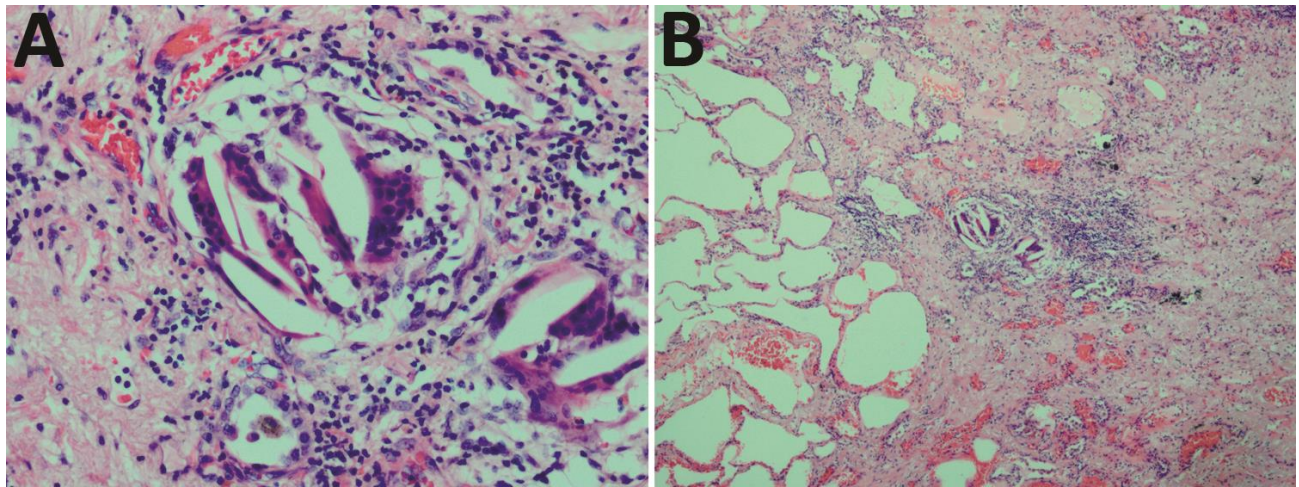


Ritual Slaughter as Overlooked Risk Factor for Brucellosis

Technical Appendix



Technical Appendix Figure. Pathologic examination results for patient with brucellosis, Israel, 2014. A) Hematoxylin/eosin stain of lung tissue, with giant cells, surrounded predominantly by lymphocytes (original magnification $\times 200$). B) Hematoxylin/eosin stain of lung tissue, showing fibrosis (right side) with a focus of giant cells, surrounded predominantly by lymphocytes (original magnification $\times 40$).

