Congenital Anomalies In Diamond Blackfan Anemia (DBA)

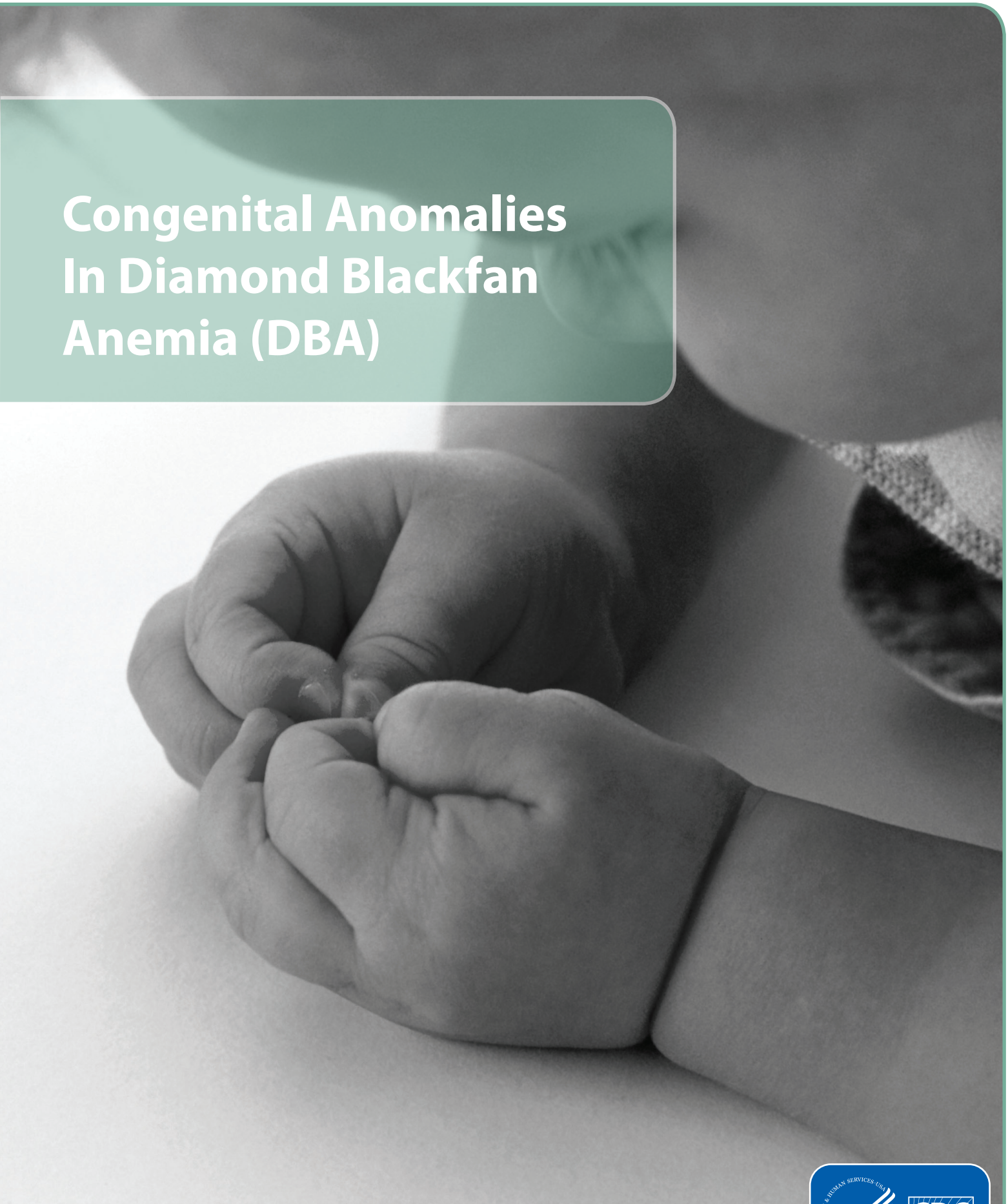

National Center on Birth Defects and Developmental Disabilities
Division of Blood Disorders

CS217857

What is a congenital anomaly?

A congenital anomaly is a structural abnormality or defect that is present at birth. Such abnormalities commonly are called "birth defects". A congenital anomaly—or birth defect—can affect any part of the body and can affect the body in different ways. Some congenital anomalies affect the way a person looks, while others affect the way a part of the body works.

What causes congenital anomalies among people with DBA?

Currently, approximately 40% of people with DBA have a mutation (alteration) in one of seven genes. All of these genes code for the cell structures which help make body proteins. Additional genetic causes of DBA will likely be identified in the future. Exactly how these mutations are related to congenital anomalies is not known. Research has shown that some congenital anomalies are more common in individuals with particular mutations. Variations in symptoms and anomalies may be due to other yet to be discovered genetic factors or environmental factors.

How common are congenital anomalies among people with DBA?

Some people with DBA will not have any congenital anomalies. However, nearly half of those with DBA will have at least one anomaly, and about one quarter of people with DBA will have more than one anomaly. The most common anomalies involve the head and face, arms and hands, heart, and genitourinary tract (including the kidneys, urinary tract, and genital organs) and are discussed in the following sections. Other less common anomalies also can occur.

How serious are congenital anomalies among people with DBA?

While the congenital anomalies that most commonly affect those with DBA are not life threatening, they can be severe. The severity can vary among persons with DBA and can differ even among family members who have DBA.

Please talk with your doctor or health care provider if you are worried about congenital anomalies.

How can I tell if I or my child has congenital anomalies?

If you or your child has DBA, it is important to be evaluated for congenital anomalies by your doctor or other health care provider. An echocardiogram or other specialized tests might be needed to look for congenital heart defects, and an ultrasound of the abdomen might be required to determine whether abnormalities in the kidneys are present.

Do congenital anomalies affect my or my child's DBA treatment?

A congenital anomaly will not affect the way you or your child responds to treatment for DBA (steroids or chronic blood transfusions).

What should I do if I or my child has a congenital anomaly?

If congenital anomalies are found, your doctor or health care provider can suggest that you see a specialist for further recommendations and treatments. Specialists might include the following:

- Orthopedic surgeon (hand and thumb anomalies)
- Urologist (urinary tract and genital organ anomalies)
- Cardiologist (heart anomalies)
- Nephrologist (kidney anomalies)
- Plastic surgeon (facial anomalies)
- Ophthalmologist (eye anomalies)
- Otolaryngologist (ear anomalies)

The treatment will depend on the number and severity of the anomalies you or your child has. A few of the available treatment options include taking special medications, getting physical therapy, and having surgery.

If you or your child has DBA, it is important to find out if other family members have congenital anomalies. Even though these family members might not have had symptoms of anemia, if they have certain congenital anomalies it might mean they have non-classical or milder forms of DBA. Testing for DBA might be recommended for them.

If you have questions about congenital anomalies, please talk with your doctor or health care provider or contact the DBA nurse Ellen Muir, RN, MSN at: 1-877-DBA-NURSe (322-6877) at: Steven and Alexandra Cohen Children's Medical Center of New York.

HANDS

About one in five people with DBA has anomalies in the hand that affect the way the hand looks, works, or both. Examples are:

TRIPHALANGEAL THUMB

Thumb with two joints instead of the one, sometimes resulting in the thumb looking like a finger.

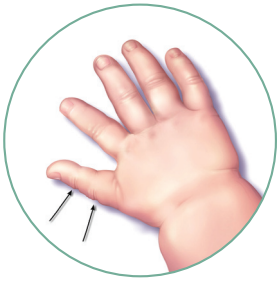

DUPLEX OR BIFID THUMB

Two thumbs on one hand or a thumb that is divided so that it looks like two thumbs.

HYPOPLASTIC THUMB

An underdeveloped thumb, which might be short, spindly, or positioned in an unusual place on the hand.

FLAT OR ABSENT THENAR EMINENCE

The muscle on the palm of the hand just below the thumb that helps to move the thumb is small or absent.

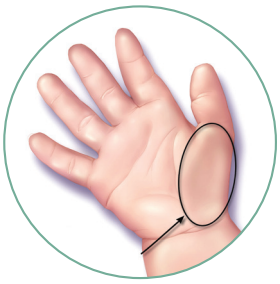

SYNDACTYLY

Fused or webbed fingers

HEAD AND FACE

The most common congenital anomalies are found on the head and face, occurring in about half of all people with DBA, and include the following anomalies:

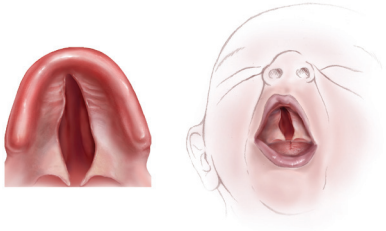

CLEFT PALATE

A hole in the roof of the mouth that can reach into the nasal cavity

"CATHIE FACIES"

A pattern of facial features which includes a short nose with a broad nasal bridge (the upper part of the nose), widely-spaced eyes, and a thick upper lip; first described by Dr. Cathie in 1951

MICROCEPHALY

Head size that is much smaller than normal for age

MICROTIA

Smaller outer ear than normal. One or both ears can be affected, and ear(s) can look different from normal or be placed lower than normal on the head. The ear canal and internal ear structure can also be malformed.

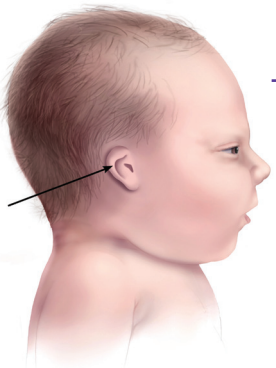

EPICANTHUS

Abnormal skin fold that covers the inner corner of the eye.

PTOSIS

Drooping eyelids.

CONGENITAL GLAUCOMA

Increased pressure inside the eyeball.

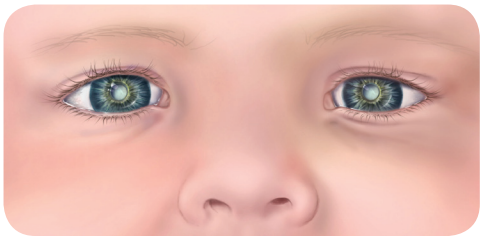

STRABISMUS

Turning of one eye so that the two eyes do not align normally.

CONGENITAL CATARACTS

Clouding of the lens of the eye.

KIDNEYS, URINARY TRACT, & GENITAL ORGANS

About one in five people with DBA have congenital abnormalities in the kidneys, urinary tract, and genital organs. Examples are:

ABSENT KIDNEY

One of the kidneys did not develop and is missing.

HORSESHOE KIDNEY

Kidneys are fused together during development to resemble the shape of a horseshoe.

HYPOSPADIAS

Urethra (the tube that drains the urine from the bladder) opens along the underside of the penis instead of at the tip.

NECK AND SHOULDERS

People with DBA can also have congenital anomalies of the neck and shoulders. Examples are:

SHORT NECK

Neck that is shorter than normal.

WEBBED NECK

Abnormal skin folds that run along the side of the neck and down to the shoulders.

SPRENGEL DEFORMITY

Shoulder blades that are underdeveloped and positioned higher on the back than normal.

KLIPPEL-FEIL MALFORMATION

Short neck, abnormal bones of the spine in the neck, a low hairline, and limited movement of the head.

HEART ANOMALIES

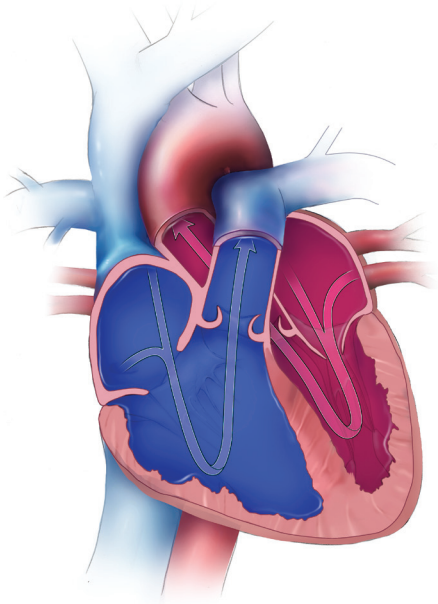

NORMAL HEART

About 3 in 20 people with DBA have congenital heart defects, including the following:

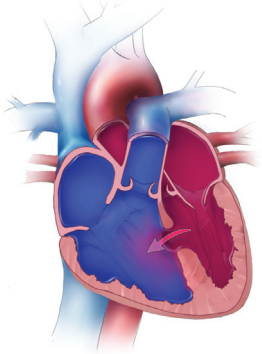

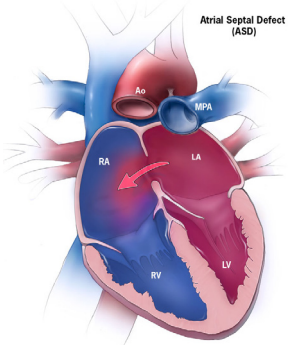

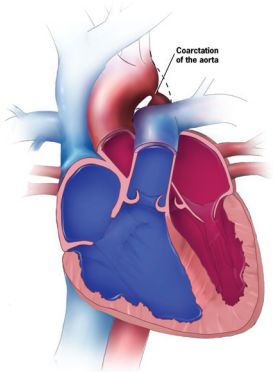

VSD (VENTRICULAR SEPTAL DEFECT)

Hole in the wall between the two ventricles, or lower chambers, of the heart, which causes abnormal flow of blood through the heart.

ASD (ATRIAL SEPTAL DEFECT)

Hole in the wall between the atria, or upper chambers, of the heart, resulting in abnormal blood flow through the heart.

COARCTATION OF THE AORTA

Narrowing of the aorta (the artery that carries oxygen rich blood away from the heart to the body), which results in increased blood pressure in the arms and head, and reduced blood pressure in the legs.

HELP IS AVAILABLE

Children with congenital anomalies are living longer, healthier lives. There are programs across the country that provide comprehensive, long-term management and care to children with congenital anomalies. If your child has a congenital anomaly, contact your health care provider to discuss your treatment options. Many times, surgery can be done to correct the anomaly. The type of surgery or treatment depends on the following:

- Type of anomaly
- Overall health of the child and medical history
- Recommendation of the health care team
- Expectations for the course of the condition
- Your opinion and preference
- Insurance coverage and cost

Many of these operations are done on an outpatient basis or require only an overnight hospital stay. The incisions usually are small, which results in less pain, faster healing, and shorter length of stays when it is necessary for your child to remain under a physician's care. Following are actual before and after photographs of a real person living with DBA who had surgery to fix a congenital anomaly.

Before

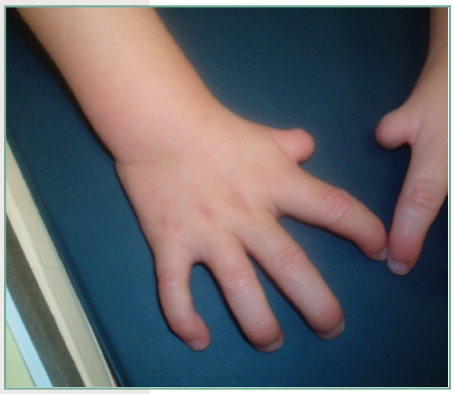

After