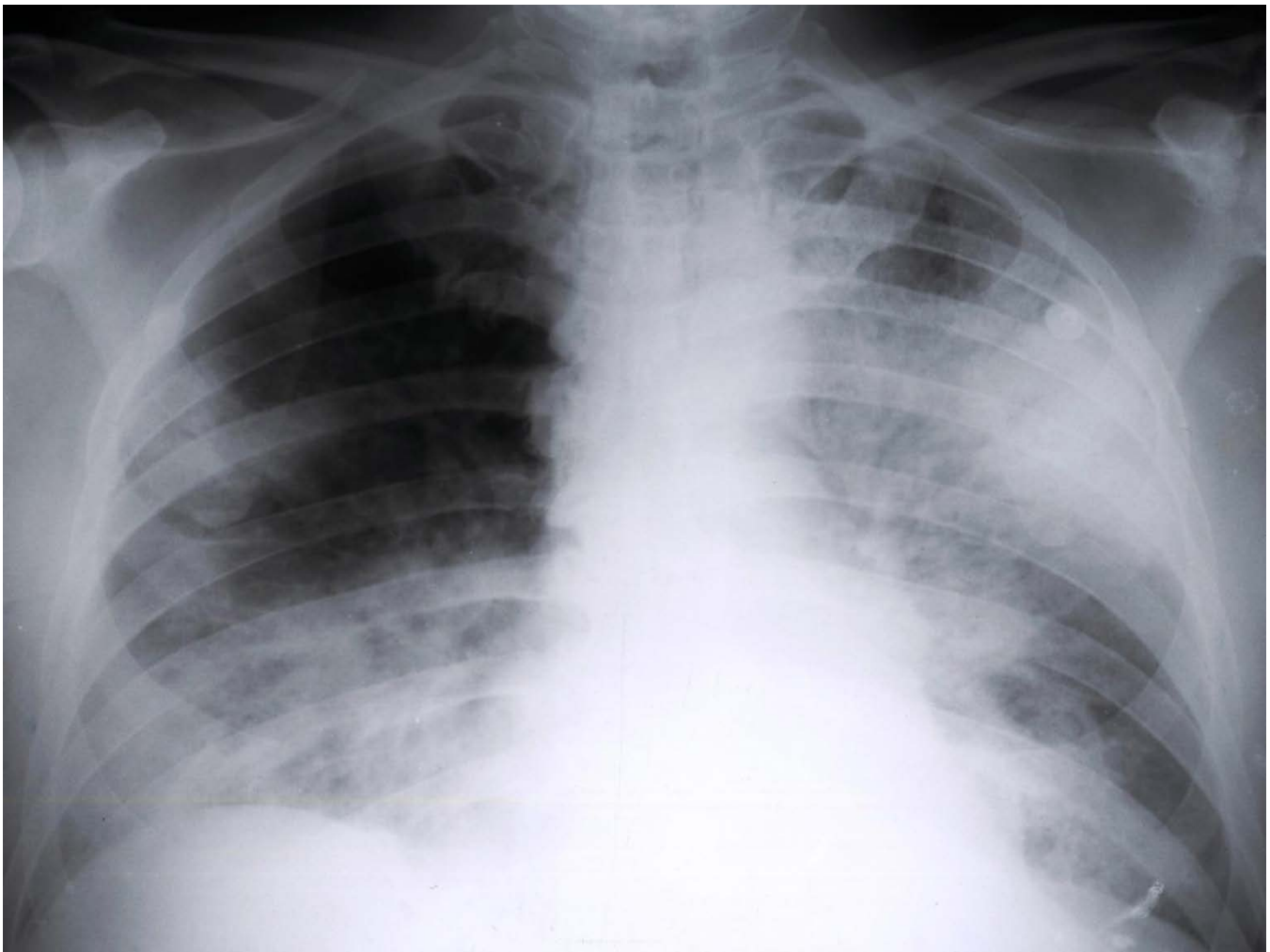


Family Cluster of Middle East Respiratory Syndrome Coronavirus Infections, Tunisia, 2013

Technical Appendix



Technical Appendix Figure. Chest radiograph of the Middle East respiratory syndrome index case-patient, taken at the time of admission to intensive care unit (May 8, 2013), Tunisia, showing pulmonary infiltrates in the entire left pulmonary field and a contralateral infiltrate in the lower half of the right pulmonary field.