

enteroaggregative *Escherichia coli* O104:H4 strains. *Int J Med Microbiol.* 2013;303:595–602. <http://dx.doi.org/10.1016/j.ijmm.2013.08.001>

Address for correspondence: Lothar Beutin, Federal Institute for Risk Assessment (BfR), National Reference Laboratory for *Escherichia coli*, Diederdsdorfer Weg 1, D-12277 Berlin, Germany; email: [lothar.beutin@bfr.bund.de](mailto:lothar.beutin@bfr.bund.de)

## Rio Mamoré Virus and Hantavirus Pulmonary Syndrome, Brazil

**To the Editor:** Hantavirus pulmonary syndrome (HPS) is an acute, severe, frequently fatal disease associated with cardiopulmonary failure; it is caused by hantaviruses naturally hosted by wild rodents. Rio Mamore virus (RIOMV) was first described in 1996 in Bolivia; it was associated with the small-eared pygmy rice rat, *Oligoryzomys microtis* (1). Subsequently, 1 strain of RIOMV was isolated from *O. microtis* rats in Peru, designated HTN-007 (2); and 2 strains were recovered in the Brazilian Amazon from *O. microtis* rats (RIOMV-3) and uncharacterized species of rodents of the genus *Oligoryzomys* (RIOMV-4) (3). Recently, HPS cases associated with RIOMV have been reported: 2 cases in Peru (4) and 1 case in French Guiana (caused by a variant named Maripa virus) (5). We report isolation of a strain of RIOMV from a patient with fatal HPS in Brazil.

In June 2011, a 28-year-old man was admitted to the Tropical Medicine Foundation Dr. Heitor Vieira Dourado, Amazonas State, with a 4-day febrile illness that included nonproductive cough, myalgia, and headache. Laboratory

testing revealed hematocrit within reference range (43.9%), thrombocytopenia (27,000 cells/mm<sup>3</sup>), elevated levels of liver enzymes (alanine transaminase 347 IU/L, aspartate transaminase 139 IU/L), creatinine (1.2 mg/dL), and urea (40 mg/dL). Laboratory testing ruled out malaria, leptospirosis, and dengue. About 24 hours after hospitalization, the patient experienced hypotension, progressive dyspnea, and acute respiratory distress. Thoracic radiographs revealed bilateral diffuse alveolar pulmonary infiltrates. Despite empirical treatment with antimicrobial drugs, mechanical ventilation, and inotropic therapy, the patient's clinical condition deteriorated and he died on day 6 after illness onset.

The patient, who had no history of travel, resided on a submerged region in the western floodplain of the Solimões-Amazon River, Amazonas, a state with low population density (6.2 persons/square mile), in a rural area of Careiro da Várzea Municipality (3°11'53"S, 59°52'18"W), where access is possible only by boat. He had a history of contact with rodents not only at home but also in the boat he used. A serum sample collected on day 6 after illness onset was evaluated for hantavirus by serologic and PCR testing. ELISA result was positive for IgM and IgG against recombinant nucleocapsid protein (N) of the Jucuitiba virus (6). Viral genome was detected by reverse transcription PCR, and the complete genomic small segment sequence, designated LH60\_11/Hu (GenBank accession no. KF584259), was determined (7). This sequence was compared with a reference panel of sequences that covered the diversity of most hantaviruses in South America and was subjected to phylogenetic analysis by MrBayes software version 3.1.2 (8). Nucleotide and amino acid sequence similarities between all taxa for the partial N gene were calculated by using MegAlign version 5.05 (DNASTAR, Inc., Madison, WI, USA). The best-fit evolution-

ary model general time reversible +  $\Gamma$  + proportion invariant was determined by using MEGA version 5.2.2 (<http://www.megasoftware.net>), and the dataset compiled only 905 nt of the N gene to include sequences of Anajatuba and Rio Mearim viruses from Brazil for comparison.

Bayesian analysis indicated that strain LH60\_11/Hu is closely associated with rodent-derived RIOMV-3/Olm strain (Itacoatiara, Amazonas State) and in a sister relationship with RIOMV-4/Olsp strain (Alto Paraíso, Rondônia State) from Brazil (Figure). Analysis of the partial sequence revealed 86.6%–95.4% of genetic identity with the strains recovered from rodents and 83.4% with the Maripa virus strain from humans. The sequence from the human patient in Peru was not available for comparison.

In July, the patient's house and environment were investigated; accumulation of garbage and other waste in homes that were still flooded was observed. We obtained and tested serum samples from 15 healthy residents (10 female, 5 male) with a recent history of acute fever; IgG against hantavirus was detected in samples from 3 women (17, 25, and 57 years of age).

This case report describes RIOMV as a highly pathogenic agent of HPS in Brazil. The location of the patient with this fulminant case of HPS, Careiro da Várzea, borders the Municipality of Itacoatiara, where RIOMV-3–infected *O. microtis* rats and the first HPS case in Amazonas State, with no etiologic identification so far, have been reported (3,9). Careiro da Várzea is part of an area in which grain production is expanding, an activity that attracts rodents to human dwellings, especially those in lowland regions that are constantly flooded.

The close association between the sequences from the human and the *O. microtis* rat (>98% aa identity) suggests that the patient might have been infected as a consequence of close physical contact with an RIOMV-

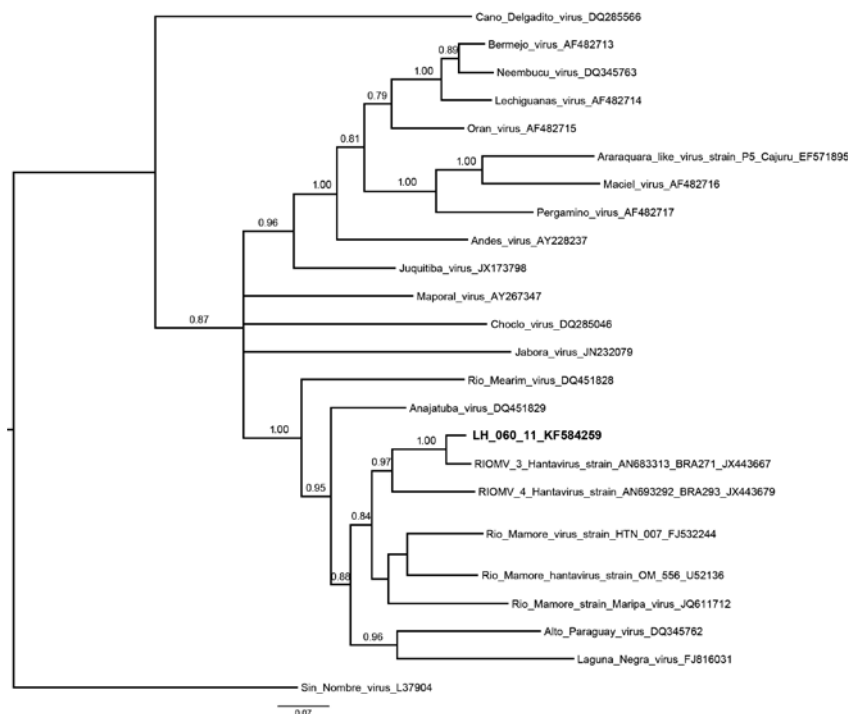


Figure. Phylogenetic relationships among hantaviruses were estimated by using the Bayesian Markov chain Monte Carlo method implemented in MrBayes version 3.1.2 (8). The relationships were based on the initial 905-nt fragment of the small segment. The numerical value  $\geq 0.7$  at the node indicates the posterior probability replicates that supported the interior branch. The branch labels include GenBank accession number and virus species or strain. Boldface indicates the reference sequence; scale bar indicates nucleotide substitutions per site. RIOMV, Rio Mamore virus.

infected *O. microtis* rat. The geographic distribution of these rats and, thus, the potential area at risk for transmission of RIOMV is vast, including 5 Brazilian states in the Amazon Basin and contiguous lowlands of Peru, Bolivia, and Paraguay (10).

This study confirms the notion that RIOMV is a highly pathogenic hantavirus. Recent recognition of RIOMV as a causative agent of HPS might be attributed to either increased awareness by local physicians or improved diagnosis of hantavirus infections. This finding emphasizes the need for extensive molecular investigation of undiagnosed infections because of the shared clinical features with other diseases endemic to this region (e.g., malaria and dengue).

This work was supported by the National Counsel for Technological and

Scientific Development—Oswaldo Cruz Foundation (grants 407664/2012-2 and 301641/2010-2) and the National Institute of Science and Technology for Viral Hemorrhagic Fevers (grant 573739/2008-0).

**Renata Carvalho de Oliveira,  
Marcelo Cordeiro-Santos,  
Alexandro Guterres,  
Jorlan Fernandes,  
Alexsandro X. de Melo,  
Guilherme A.P. João,  
Maria A.M. Novais,  
Elizabeth Salb e  
Travassos da Rosa,  
Pedro Fernando  
da Costa Vasconcelos,  
Stefan Vilges de Oliveira,  
Bernardino Cl audio  
de Albuquerque,  
and Elba Regina  
Sampaio de Lemos**

Author affiliations: Oswaldo Cruz Foundation, Rio de Janeiro, Brazil (R.C. Oliveira, A. Guterres, J. Fernandes, E.R.S. Lemos); Health Surveillance Foundation, Manaus, Brazil (M. Cordeiro-Santos, A.X. de Melo, M.A.M. Novais, B.C. Albuquerque); Amazon State University, Manaus (M. Cordeiro-Santos); Tropical Medicine Foundation, Manaus (G.A.P. Jo ao); Evandro Chagas Institute, Bel em, Brazil (E.S. Travassos da Rosa, P.F.C. Vasconcelos); Ministry of Health, Bras lia, Brazil (S. Vilges de Oliveira); Amazon Federal University, Manaus (B.C. Albuquerque); and Par  State University, Bel em (P.F.C. Vasconcelos)

DOI: <http://dx.doi.org/10.3201/eid2009.131472>

## References

1. Bharadwaj M, Botten J, Torrez-Martinez N, Hjelle B. Rio Mamor  virus: genetic characterization of a newly recognized hantavirus of the pygmy rice rat, *Oligoryzomys microtis*, from Bolivia. *Am J Trop Med Hyg.* 1997;57:368–74.
2. Powers AM, Mercer DR, Watts DM, Guzman H, Fulhorst CF, Popov VL, et al. Isolation and genetic characterization of a hantavirus (Bunyaviridae: Hantavirus) from a rodent, *Oligoryzomys microtis* (Muridae), collected in northeastern Peru. *Am J Trop Med Hyg.* 1999;61:92–8.
3. Firth C, Tokarz R, Simith DB, Nunes MRT, Bhat M, Rosa EST, et al. Diversity and distribution of hantaviruses in South America. *J Virol.* 2012;86:13756–66. <http://dx.doi.org/10.1128/JVI.02341-12>
4. Casapia M, Mamani E, Garcia MP, Miraval ML, Valencia P, Quino AH, et al. Hantavirus pulmonary syndrome (Rio Mamore virus) in the Peruvian Amazon region [in Spanish]. *Rev Peru Med Exp Salud Publica.* 2012;29:390–5. <http://dx.doi.org/10.1590/S1726-46342012000300016>
5. Matheus S, Lavergne A, De Thoisy B, Dussart P, Lacoste V. Complete genome sequence of a novel hantavirus variant of Rio Mamor  virus, Maripa virus, from French Guiana. *J Virol.* 2012;86:5399. <http://dx.doi.org/10.1128/JVI.00337-12>
6. Raboni SM, Levis S, Rosa EST, Bisordi I, Delfraro A, Lemos E, et al. Hantavirus infection in Brazil: development and evaluation of an enzyme immunoassay and immunoblotting based on N recombinant protein. *Diagn Microbiol Infect Dis.* 2007;58:89–97. <http://dx.doi.org/10.1016/j.diagmicrobio.2006.11.012>
7. Guterres A, de Oliveira RC, Fernandes J, D'Andrea PS, Bonvicino CR, Bragagnolo C, et al. Phylogenetic analysis of the

- S segment from Jujutiba hantavirus: identification of two distinct lineages in *Oligoryzomys nigripes*. *Infect Genet Evol.* 2013;18:262–8. <http://dx.doi.org/10.1016/j.meegid.2013.05.027>
8. Ronquist F, Huelsenbeck JP. MrBayes 3: Bayesian phylogenetic inference under mixed models. *Bioinformatics.* 2003;19:1572–4. <http://dx.doi.org/10.1093/bioinformatics/btg180>
  9. dos Santos MC, De Lacerda MVG, Benedetti SM, Albuquerque BC, De Aguiar Filho AABV, Elkhoury MDR, et al. Human hantavirus infection, Brazilian Amazon. *Emerg Infect Dis.* 2006;12:1165–7. <http://dx.doi.org/10.3201/eid1207.060074>
  10. Musser GG, Carleton MD. Superfamily Muroidea. In: Wilson DE, Reeder DM, editors. *Mammal species of the world: a taxonomic and geographic reference*. 3rd ed. Baltimore: Johns Hopkins University Press; 2005. p. 849–1531.

Address for correspondence: Renata C. de Oliveira, Pavilhão Hélio e Peggy Pereira, Sala B115, Instituto Oswaldo Cruz, FIOCRUZ, Avenida Brasil 4365, Manguinhos, 21040-900, Rio de Janeiro/RJ, Brazil; email: reoliveira@ioc.fiocruz.br

## Reemergence of *Brucella melitensis* in Wildlife, France

**To the Editor:** Brucellosis is a worldwide zoonosis caused by *Brucella* spp. France has been free of bovine, ovine, and caprine brucellosis (caused by *B. abortus* or *B. melitensis*) since 2003 (1). In early 2012, an outbreak of bovine and human brucellosis caused by *B. melitensis* biovar 3 (*Bme13*) occurred in a French Alp massif (mountainous region), where the last reported outbreak occurred in 1999 (online Technical Appendix Figure, <http://wwwnc.cdc.gov/EID/article/20/9/13-1517-Techapp1.pdf>) (2). This outbreak suggested the

persistence or reemergence of *Brucella* spp. in livestock.

An extensive investigation was conducted that involved 40 animal herds with direct links to the outbreak. Six months later, blood samples from each adult animal in any herd (12,116 animals in 205 herds) that grazed during the summer of 2012 in the massif underwent serologic analysis. However, no other case was identified in this population (online Technical Appendix Table 1). Therefore, a potential wildlife source was investigated.

Wild ruminants in the study area were the following species: hunted red deer (*Cervus elaphus*), roe deer (*Capreolus capreolus*), chamois (*Rupicapra rupicapra*), and protected Alpine ibex (*Capra ibex*). Although *B. abortus* and *B. suis* have been reported in numerous wildlife species (3), *B. melitensis* has rarely been isolated from wildlife, and only sporadic cases of infection have been reported in Europe, in chamois and Alpine ibex in the Alps (4,5) and in Iberian ibex (*Capra pyrenaica hispanica*) in the Pyrenees (6). These cases were considered to be caused by spillover from domestic ruminants, which suggests that these wild species are unable to sustain the infection (3).

We conducted our investigation during the fall–winter of 2012–2013 in the entire massif where the outbreak occurred. Blood, lung, spleen, and testes or uterus samples were obtained from all hunted animals. French Authorities authorized the killing of 12 seropositive or diseased Alpine ibex with clinical signs of brucellosis (i.e., arthritis or orchitis) among 30 captured animals.

All serum samples were tested according to requirements of the World Organisation for Animal Health for diagnosis of brucellosis in small ruminants by using by the Rose Bengal test (RBT) and the complement fixation test (CFT) (7), and by indirect ELISA (IDEXX, Montpellier, France) and competitive ELISA

(cELISA; Ingenasa, Madrid, Spain). When blood samples were unsuitable for RBT or CFT or were missing, a lung extract was tested by only the 2 ELISAs. Culture was only performed on samples from seropositive animals (online Technical Appendix Table 1) (8). If bacteriologic results were negative, a *Brucella* genus–specific real-time PCR was also used (9).

A total of 129 hunted ruminants (55 chamois, 30 red deer, 44 roe deer) were tested. No clinical signs were observed, except for arthritis in the knee of 1 chamois. All ruminants were seronegative except for the chamois, which showed positive results in the RBT, CFT, and cELISA, and 1 red deer, which showed a weakly positive result in the cELISA, but negative results by culture and real-time PCR. *Bme13* was isolated from the chamois (online Appendix Table 1).

Among 289 Alpine ibex observed in the massif, 24 were killed (22 randomly sampled animals that showed 2 diagnostic lesions at necropsy [arthritis in the knee and mammary abscesses] and 2 diseased animals [arthritis in the knee and orchitis]), and samples from these animals were subjected to serologic analysis. Ten Alpine ibex (including the 2 diseased animals) showed positive results in the RBT, CFT, and both ELISAs, and 2 showed positive results only for both ELISAs. Thus, the prevalence of *B. melitensis* in randomly captured animals was 45% (10/22; 95% CI 24.6%–66.3%) (online Technical Appendix Table 1).

*Bme13* was isolated from 5 of 11 seropositive Alpine ibex (1 Alpine ibex was killed in an avalanche). Three seropositive but culture-negative ibex showed positive results by PCR (online Technical Appendix Table 2). Multilocus variable number tandem repeat analysis showed similarity among all strains isolated in this study and strains isolated from local domestic outbreaks >13 years ago (10).