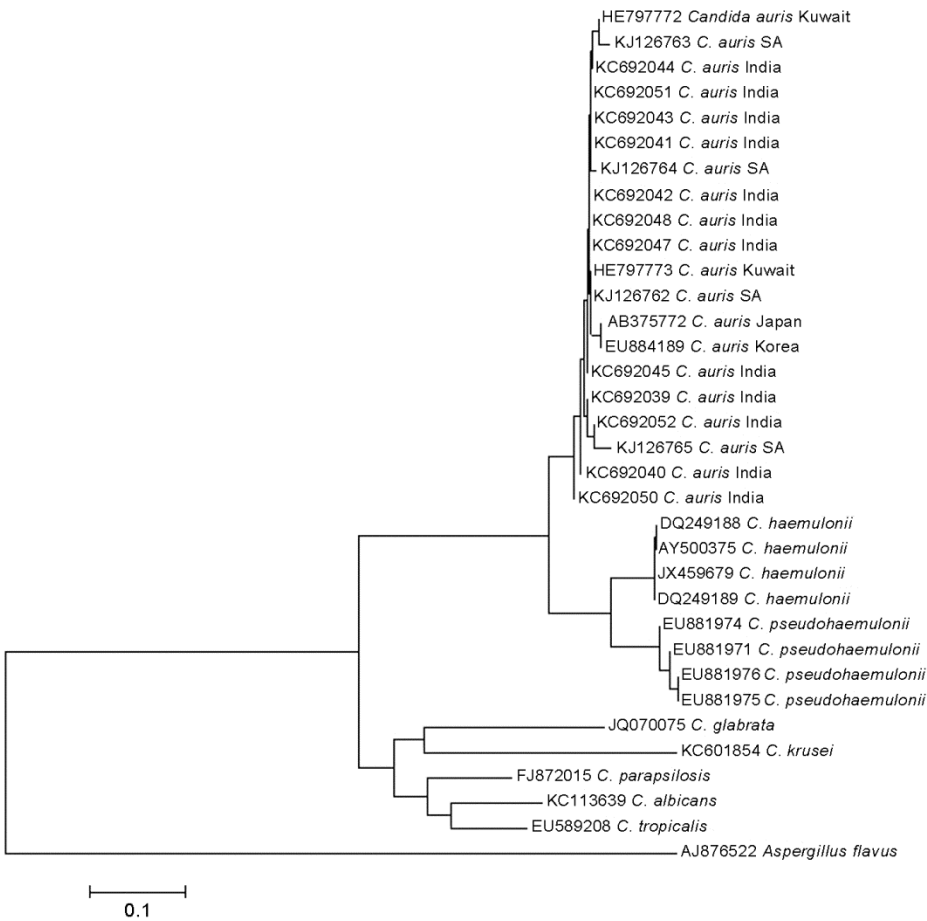


Candida auris–Associated Candidemia, South Africa

Technical Appendix



Technical Appendix Figure. Phylogenetic relatedness of internal transcribed spacer region of the ribosomal RNA gene of *Candida auris* with closely related *Candida* species. Scale bar indicates nucleotide substitutions per site.

Technical Appendix Table. Clinical characteristics of a 73-year-old male patient with candidemia caused by *Candida auris*, South Africa

Isolate ID	Risk factor	Antifungal treatment	Outcome
224	<p>Referred to a public-sector specialist burn unit from a private-sector hospital</p> <p>40% third-degree burns with inhalational injury; required débridement, skin grafts, and tracheostomy</p> <p>In situ: central venous catheter/s, arterial line, urinary catheter</p> <p>Mechanically ventilated</p> <p>Multiple episodes of sepsis requiring broad-spectrum antimicrobial drugs, including β-lactams, colistin, linezolid, and vancomycin</p> <p>Renal failure requiring hemodialysis</p>	Amphotericin B deoxycholate (received only 1 dose)	Died 35 d after admission to hospital