

- Verhaegh SJ, Snippe ML, Levy F, Verbrugh HA, Jaddoe VW, Hofman A, et al. Colonization of healthy children by *Moraxella catarrhalis* is characterized by genotype heterogeneity, virulence gene diversity and co-colonization with *Haemophilus influenzae*. *Microbiology*. 2011;157:169–78. <http://dx.doi.org/10.1099/mic.0.042929-0>
- Sturm AW, Mostert R, Rouing PJ, van Klengeren B, van Alphen L. Outbreak of multiresistant non-encapsulated *Haemophilus influenzae* infections in a pulmonary rehabilitation centre. *Lancet*. 1990;335:214–6. [http://dx.doi.org/10.1016/0140-6736\(90\)90291-C](http://dx.doi.org/10.1016/0140-6736(90)90291-C)
- Spaniol V, Troller R, Aebi C. Physiologic cold shock increases adherence of *Moraxella catarrhalis* to and secretion of interleukin 8 in human upper respiratory tract epithelial cells. *J Infect Dis*. 2009;200:1593–601. <http://dx.doi.org/10.1086/644640>

Address for correspondence: Shigeru Fujimura, Research Division for Development of Anti-Infective Agents, Institute of Development, Aging and Cancer, Tohoku University, 4-1, Seiryomachi, Aoba-ku, Sendai, 980-8575, Japan; email: fujimo@idac.tohoku.ac.jp

## Severe Pneumonia Caused by *Legionella* *pneumophila* Serogroup 11, Italy

**To the Editor:** *Legionella pneumophila* serogroups (SGs) 1–16 cause pneumonia in humans. Although SG 1 is the serogroup most commonly associated with disease (1), we report a case of community-acquired legionellosis caused by SG 11.

In November 2010, a 42-year-old man was admitted to Modena University Hospital, Modena, Italy, with a 4-day history of fever, dyspnea, and cough. His vital signs were as follows: temperature 40.0°C, pulse 135 beats/min, blood pressure 110/60 mm

Hg, respiratory rate 30 breaths/min, and oxygen saturation 85% in room air. Inspiratory crackles were heard in the left lower lung lobe. Chest radiographs and successive high-resolution computerized tomography revealed left lobar infiltrates (Figure, panels A and B). Blood count documented severe pancytopenia together with high levels of inflammation markers: fibrinogen (1,031 mg/dL), C-reactive protein (33 mg/dL), and procalcitonin (28.5 ng/mL). The patient's medical history was unremarkable; however, results of tests conducted at the time of hospital admission led to the diagnosis of acute leukemia.

Empirically prescribed antimicrobial treatment for neutropenic patients was initiated and consisted of meropenem (3 g/day) and levofloxacin (500 mg/day), combined first with

vancomycin (2 g/day) and later with linezolid (1,200 mg/day). A few days later, antifungal therapy was empirically added to the treatment regimen (liposomal amphotericin B at 3 mg/kg/day). The patient received continuous positive airway pressure, which resulted in progressive improvement of blood gas exchange, until normalization was achieved.

Serologic and molecular examination and culture of bronchoalveolar lavage fluid, blood, urine, and feces produced negative results for fungal, viral, and bacterial pathogens. Test results for *L. pneumophila* urinary antigen (Biotest AG, Dreieich, Germany) and IgM and IgG against *L. pneumophila* (Serion-Immundiagnostica GmbH, Würzburg, Germany) were negative. Culture of sputum collected at the time of

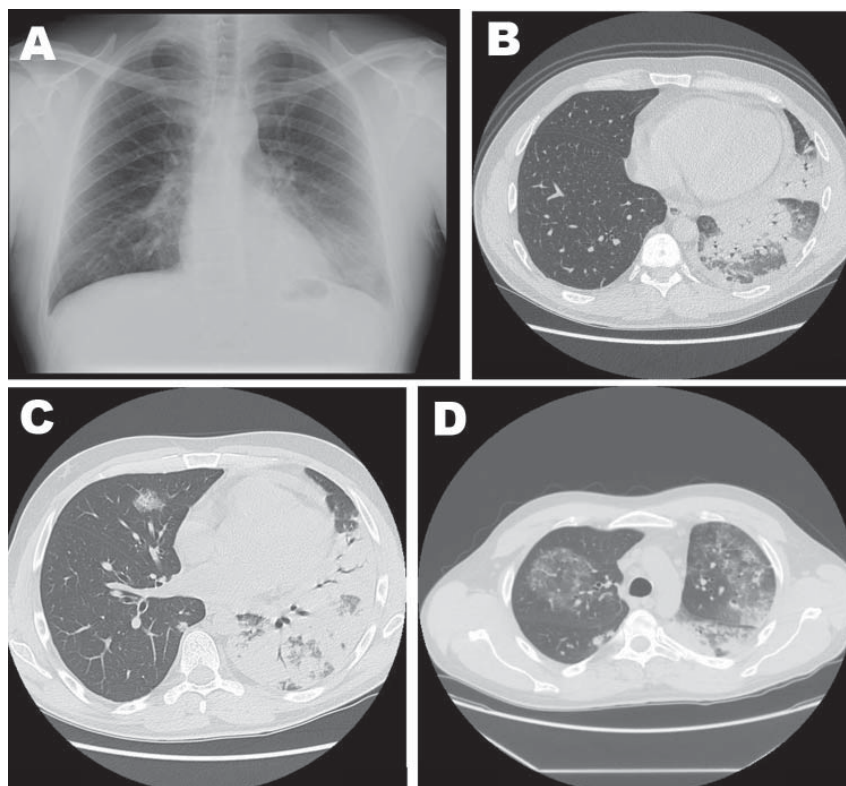


Figure. Imaging studies of 42-year-old man with severe pneumonia caused by *Legionella pneumophila* serogroup 11, showing lobar consolidation of the left lower lung lobe, with an air-bronchogram within the homogeneous airspace consolidation. Consensual mild pleural effusion was documented by a chest radiograph (A) and high-resolution computed tomography (B). A week after hospital admission, repeat high-resolution computerized tomography of the chest showed extensive and homogeneous consolidation of left upper and lower lobes, accompanied by bilateral ground-glass opacities (C and D).

hospital admission showed growth of legionella-like colonies on buffered charcoal yeast extract, with and without the addition of antimicrobial drugs (Oxoid, Basingstoke, UK). The colonies were identified as *L. pneumophila* SGs 2–14 by the *Legionella* latex test (Oxoid). The strain was further characterized as *L. pneumophila* SG 11, according to a polyclonal latex reagent set (Biolife, Milan, Italy). Environmental investigations were conducted in the patient's house and workplace, but *L. pneumophila* SG 11 was not detected in any of the locations tested.

A week after hospital admission, the patient was persistently febrile and experienced pain in the left thorax. High-resolution computerized tomography of the chest was repeated and showed increased pulmonary infiltrate (Figure, panels C and D) that was consistent with *L. pneumophila* pneumonia (2). Highly potent antimicrobial therapy against *L. pneumophila* was administered, consisting of high-dosage levofloxacin (1 g/day) combined with azithromycin (500 mg/day), while the other antimicrobial agents were progressively reduced (3). The fever subsided 14 days after the onset of targeted antimicrobial drug treatment; at that time, the sputum culture and test results for urinary *L. pneumophila* antigen were negative, but serologic assay results were positive for IgG and negative for IgM against *L. pneumophila*. Subsequent computerized tomographic scans of the chest documented progressive improvement of lung infiltrates, and nearly complete resolution was obtained 3 months after hospital admission.

*L. pneumophila* SG 11 infection has, thus far, been reported only rarely in humans. The first SG 11 strain was isolated in the United States in 1982 from a patient with multiple myeloma (4). Since then, few other cases of SG 11 strains have been reported in Europe (5,6); it is conceivable that

this strain is not as widely distributed and is less pathogenic than other SGs, especially SG 1. It can be argued that infections caused by SG 11 have been underdiagnosed. *L. pneumophila* SG 11 cannot be detected by *Legionella* urinary antigen or serologic tests, the assays most frequently used to diagnose legionellosis (7–9). The negative urinary antigen test result for this patient is consistent with a non-SG 1 infection. The single positive serologic result for IgG was probably caused by cross-reactivity because the commercial assay kit was designed to recognize only *L. pneumophila* SGs 1–7. Culture is the only useful diagnostic tool for identifying SGs. However, this tool is not always feasible because it requires specialized media and skills to identify the organism. In addition, sensitivity is low, depending on the severity of the disease and the availability of adequate respiratory specimens (9). Despite these limitations, culture is needed to detect all SGs of *L. pneumophila*, especially in immunocompromised patients, who are more susceptible to infections caused by strains of non-SG 1 *L. pneumophila* (10).

#### Acknowledgments

We thank Teresa Stocki and Massimo Mentasti for their technical expertise and Valeria Fantuzzi and Franco Narni, who took care of the patient. We are grateful to Alice Artioli for linguistic revision of the manuscript.

This work was supported by the National Health Service.

**Antonella Grottola,  
Fabio Forghieri, Marisa Meacci,  
Anna Fabio, Lorena Pozzi,  
Patrizia Marchegiano,  
Mauro Codeluppi,  
Monica Morselli,  
Leonardo Potenza,  
Ambra Paolini, Valeria Coluccio,  
Mario Luppi, Fabio Rumpianesi,  
and Monica Pecorari**

Author affiliations: University Hospital-Policlinico, Modena, Italy; and University of Modena and Reggio Emilia, Modena

DOI: <http://dx.doi.org/10.3201/eid1811.120216>

#### References

1. Palusińska-Szyszk M, Cendrowska-Pinkosz M. Pathogenicity of the family *Legionellaceae*. *Arch Immunol Ther Exp (Warsz)*. 2009;57:279–90. <http://dx.doi.org/10.1007/s00005-009-0035-8>
2. Yu H, Higa F, Hibiya K, Furugen M, Sato Y, Shinzato T, et al. Computed tomographic features of 23 sporadic cases with *Legionella pneumophila* pneumonia. *Eur J Radiol*. 2010;74:e73–8. <http://dx.doi.org/10.1016/j.ejrad.2009.04.011>
3. Sabrià M, Pedro-Botet ML, Gómez J, Roig J, Vilaseca B, Sopena N, et al.; Legionnaires Disease Therapy Group. Fluoroquinolones vs macrolides in the treatment of Legionnaires disease. *Chest*. 2005;128:1401–5. <http://dx.doi.org/10.1378/chest.128.3.1401>
4. Thacker WL, Benson RF, Wilkinson HW, Ampel NM, Wing EJ, Steigerwalt AG, et al. 11th serogroup of *Legionella pneumophila* isolated from a patient with fatal pneumonia. *J Clin Microbiol*. 1986;23:1146–7.
5. Helbig JH, Bernander S, Castellani Pastoris M, Etienne J, Gaia V, Lauwers S, et al. Pan-European study on culture-proven Legionnaires' disease: distribution of *Legionella pneumophila* serogroups and monoclonal subgroups. *Eur J Clin Microbiol Infect Dis*. 2002;21:710–6. <http://dx.doi.org/10.1007/s10096-002-0820-3>
6. Wewalka G, Schmid D, Harrison TG, Uldum SA, Lück C. Cases of dual infections with different *Legionella* strains. Presented at the 26th meeting of the European Working Group for *Legionella* Infections (EWGLI); 2011 May 25–27; Vienna, Austria. Stockholm: The Group; 2011.
7. European Centre for Disease Prevention and Control. Legionnaires' disease in Europe 2009. Stockholm: The Centre; 2011. p. 9.
8. Shimada T, Noguchi Y, Jackson JL, Miyashita J, Hayashino Y, Kamiya T, et al. Systematic review and meta-analysis: urinary antigen tests for legionellosis. *Chest*. 2009;136:1576–85. <http://dx.doi.org/10.1378/chest.08-2602>
9. Blyth CC, Adams DN, Chen SCA. Diagnostic and typing methods for investigating *Legionella* infection. *N S W Public Health Bull*. 2009;20:157–61. <http://dx.doi.org/10.1071/NB08062>

10. Jacobson KL, Miceli MH, Tarrand JJ, Kontoyiannis DP. *Legionella* pneumonia in cancer patients. *Medicine (Baltimore)*. 2008;87:152–9. <http://dx.doi.org/10.1097/MD.0b013e3181779b53>

Address for correspondence: Antonella Grottola, Unit of Microbiology and Virology, Regional Reference Laboratory for Clinical Diagnosis of Legionellosis, University Hospital-Policlinico, Via del Pozzo71, 41124 Modena, Italy; email: [antonella.grottola@unimore.it](mailto:antonella.grottola@unimore.it)

## Novel Human Enterovirus C Infection in Child with Community-acquired Pneumonia

**To the Editor:** Human enteroviruses (HEVs) are small, nonenveloped viruses with a positive-stranded RNA genome that includes regions P1, P2, and P3 (1). Most experts believe that HEV strains with >75% nt and >85% aa identity in complete or partial viral protein 1 (VP1) sequences should be considered the same type (2). However, more stringent criteria of 75% nt and 88% aa identity have been suggested for routine typing (3). We report the isolation and characterization of a novel HEV type within the species HEV-C (designated EV-C117 by the *Picornaviridae* Study Group, [www.picornastudygroup.com/](http://www.picornastudygroup.com/)).

A 45-month-old boy was admitted to a hospital in Vilnius, Lithuania, in December 2010 after 1 day of high fever (temperature 40°C) with cough and a moderately increased respiratory rate (36 breaths/min). Decreased breath sounds were heard at the base of the left lung during auscultation, and a chest radiograph showed alveolar

pneumonia with partial consolidation of the lower lobe of the left lung. The patient had a leukocyte count of 23,900 cells/mm<sup>3</sup> and C-reactive protein level of 9.6 mg/dL. Blood culture results were negative for bacteria and fungi. The patient was treated with cefuroxime (500 mg every 8 h) for 7 days. Oxygen administration was not required because the saturation level of peripheral oxygen was always >97%. The patient was discharged in good clinical condition after 7 days and did not experience clinical problems in the following 4 weeks.

For research purposes, a nasopharyngeal sample was collected from the boy at hospital admission by using a flexible pernasal flocked swab; written informed consent was obtained from the parents. The swab was immediately placed in a minitube containing 1 mL of universal transport medium (UTM-RT Kit; Copan Italia, Brescia, Italy). The sample was stored at 4°C in the hospital laboratory before being sent to the central laboratory at the University of Milan, Italy in a refrigerated package. We extracted viral nucleic acids from the swab sample by using an automated extraction system (NucliSens easyMAG; Biomeriëux, Craponne, France), and we tested the extract for respiratory viruses by using the Respiratory Virus Panel (Fast assay (Luminex Molecular Diagnostics Inc., Toronto, Ontario, Canada) in accordance with the manufacturer's instructions (4).

The assay result was positive for bocavirus and enterovirus/rhinovirus, so we retested the sample to identify the rhinovirus. We performed real-time reverse transcription PCR by using the AgPath-ID One-Step RT-PCR Kit (Applied Biosystems, Foster City, CA, USA) and primers and probe sequences reported by Lu et al. (5). Phylogenetic analysis of the VP4/VP2 region showed that some nucleotide sequences belonged to enterovirus species. We obtained

a partial VP1 sequence by using the primers described by Nix et al. (6), and we obtained the remaining sequence of the VP1 capsid region by using in-house amplification and sequencing protocols (available upon request). The complete P1 sequence was submitted to the *Picornaviridae* Study Group, compared with other enterovirus sequences, and designated as a proposed new type of enterovirus, EV-C117 (GenBank accession no. JQ446368).

To obtain additional viral sequences, we analyzed and sequenced the complete P1 capsid region. This region was compared with the matching region of all of the complete enterovirus genomes available in the GenBank database (as of January 20, 2012). On the basis of the nucleotide sequences, we reconstructed a phylogenetic tree by using maximum likelihood methods with the Tamura 3-parameter model as the evolutionary model; rates among sites were heterogeneous, and gamma distribution was used for the relative rate (7). The closest genotypes were EV-C104 (GenBank accession no. EU840733) and EV-C109 (GenBank accession no. NC014336) (Figure). The VP4 genomic region had the greatest identity with other HEV strains; the VP1 coding region had the lowest identity.

We report the identification of a novel enterovirus (designated EV-C117) in a child hospitalized with community-acquired pneumonia in Vilnius, Lithuania. EV-C117 was detected in the child in association with bocavirus. Although it is not possible to say whether this new enterovirus was the etiologic cause of the disease, a close relationship has been found (mainly in children) between the development of severe lower respiratory tract infections requiring hospitalization and infections caused by EV-68 (8) and EV-C104 and EV-C109 (9), which are molecularly similar to EV-C117.