

References

- Berlin C. *Leishmania* recidiva cutis. *Leishmanid Arch Dermatol Syphilol*. 1940;41:874–86.
- Calvopina M, Uezato H, Gomez EA, Korenaga M, Nonaka S, Hashiguchi Y. Leishmaniasis recidiva cutis due to *Leishmania* (*Viannia*) *panamensis* in subtropical Ecuador: isoenzymatic characterization. *Int J Dermatol*. 2006;45:116–20.
- Rotureau B, Ravel C, Nacher M, Couppie P, Curtet I, Dedet JP, et al. Molecular epidemiology of *Leishmania* (*Viannia*) *guyanensis* in French Guiana. *J Clin Microbiol*. 2006;44:468–73.
- Dedet JP, Pradinaud R, Gay F. Epidemiological aspects of human cutaneous leishmaniasis in French Guiana. *Trans R Soc Trop Med Hyg*. 1989;83:616–20.
- Oliveira-Neto MP, Mattos M, Souza CS, Fernandes O, Pirmez C. Leishmaniasis recidiva cutis in New World cutaneous leishmaniasis. *Int J Dermatol*. 1998;37:846–9.
- Cannavo SP, Vaccaro M, Guarneri F. Leishmaniasis recidiva cutis. *Int J Dermatol*. 2000;39:205–6.
- Lightburn E, Morand JJ, Meynard JB, Kraemer P, Chaudier B, Pages F, et al. Management of American cutaneous leishmaniasis: outcome of high-dose pentamidine isethionate treatment of 326 cases. *Med Trop (Mars)*. 2003;63:35–44.
- Roussel M, Nacher M, Fremont G, Rotureau B, Clyti E, Sainte-Marie D, et al. Comparison between one and two injections of pentamidine isethionate, at 7 mg/kg in each injection, in the treatment of cutaneous leishmaniasis in French Guiana. *Ann Trop Med Parasitol*. 2006;100:307–14.
- Mendonça MG, de Brito ME, Rodrigues EH, Bandeira V, Jardim ML, Abath FG. Persistence of *Leishmania* parasites in scars after clinical cure of American cutaneous leishmaniasis: is there a sterile cure? *J Infect Dis*. 2004;189:1018–23.
- Marovich MA, Lira R, Shepard M, Fuchs GH, Kreutzer R, Nutman TB, et al. Leishmaniasis recidivans recurrence after 43 years: a clinical and immunologic report after successful treatment. *Clin Infect Dis*. 2001;33:1076–9.

Address for correspondence: Jean-Pierre Gangneux, Laboratoire de Parasitologie-Mycologie, Hôpital Pontchaillou, 2 Rue Henri Le Guilloux, 35033 Rennes CEDEX 9, France; email: jean-pierre.gangneux@univ-rennes1.fr

All material published in Emerging Infectious Diseases is in the public domain and may be used and reprinted without special permission; proper citation, however, is required.

Leprosy as Immune Reconstitution Inflammatory Syndrome in HIV-positive Persons

To the Editor: More than 2 decades ago, when HIV was first detected, many investigators predicted the rise of leprosy secondary to opportunistic infection (1). Recently, the phenomenon of immune reconstitution inflammatory syndrome (IRIS), or leprosy reversal response, has received attention. IRIS often occurs secondary to initiating highly active antiretroviral therapy (HAART). The first indications of an interaction between HIV and *Mycobacterium leprae* occurred only recently, with the identification of IRIS after initiation of HAART in patients with HIV and previously undetected leprosy. A review by Pustianowski et al. discusses the paradox of HIV and leprosy with IRIS (2). In addition, Lawn et al. described the first case of IRIS after the onset of HAART in a patient who had tuberculoïd leprosy that was never confirmed by molecular analysis (3).

Multiple reports (4–7) unmasked subclinical Hansen disease (*M. leprae* infection) occurring with HAART or spontaneously (8). In case reports by Lu et al. (6) and Sharma et al. (7), leprosy was associated with erythema nodosum leprosum. Pereira et al. discovered that patients known to have HIV and leprosy, when treated with HAART manifested a type 1 reversal reaction, acute leprosy inflammatory episode (4), or IRIS. We describe the first, to our knowledge, 2 cases in the United States of HIV and leprosy infections in which IRIS has occurred after HAART initiation and which has been confirmed by molecular analysis.

Three skin-biopsy samples, 2 from patient 1 and 1 from patient 2, were analyzed to confirm the presence of *M. leprae*. Patient 1 met the diagnostic criteria for leprosy according

to biopsy result; patient 2's case was compatible with such criteria. Each patient was treated for leprosy, and each responded favorably. The purpose of our case study was to confirm *M. leprae* DNA in skin samples. The skin specimens were paraffin-embedded slides. DNA was extracted by standard molecular biologic methods that used xylene. PCR amplified the *M. leprae* heat shock protein 65 gene (*hsp65*). After amplification, restriction fragment-length polymorphism (RFLP)–polyacrylamide gel electrophoresis (PAGE) was performed with *HaeIII* (6).

Patient 1 was a 60-year-old Hispanic man who was first evaluated in Los Angeles, California, with skin lesions covering >50% of his body. He reported having erythematous scaly plaques that had been waxing and waning for several months. Several skin biopsy samples were taken, and an HIV test was conducted; results showed that he had lepromatous leprosy and was HIV positive. Biopsy specimens were both Fite stain positive for numerous acid-fast bacilli. Three months after HAART was initiated, repeat skin biopsy samples were taken from nodules that had recently developed on his right arm and torso. Histologic assessment showed Fite stain–positive granulomatous dermatitis with many foamy cells. He was treated for leprosy and is continuing HAART.

Patient 2 was a 37-year-old West African black man from Burkina Faso who was evaluated in New York for gram-negative bacteremia. He was admitted and treated for disseminated salmonellosis and was found to be HIV positive. His T-lymphocyte count was 7/μL. He was promptly prescribed HAART and responded well to treatment: his T-cell count rose to 112/μL during 5 months and is currently >700/μL. Within 2 years of HAART initiation, multiple anesthetic, hypopigmented skin macules that failed to resolve over 6 months

developed. These macules developed further into nodules. Punch biopsy results were consistent with granulomatous dermatitis. Fite stain was negative for acid-fast bacilli, but leprosy was diagnosed on the basis of anesthesia localized to his skin lesions. When the biopsy samples were taken, the patient was receiving dapson in addition to HAART. Rifampin treatment was started subsequent to biopsies.

PCR amplification for *M. leprae* *hsp65* was positive for all 3 samples. Thus, mycobacterial DNA was present in both patients. The RFLP analysis results are shown in the Figure. The *hsp65* RFLP pattern for patient 1 was identical to those described by Martiniuk et al. (9) and for the wild-type pattern for patient 2, as shown by Lu et al. (6), thus demonstrating the presence of *M. leprae* DNA in these samples.

Previous studies have highlighted the low rate of HIV and leprosy co-infection. For example in Ethiopia, Frommel et al. noted that, before HAART was available in resource-poor settings, increased HIV seropositivity did not alter the natural course of leprosy nor increase the number of patients with *M. leprae* (10). Nevertheless, positive reports of IRIS and leprosy after initiation of HAART have been reported from other nations (3–5). If this syndrome can be detected even in the mildly leprosy–endemic United States (8), an increase in similar cases in areas where HIV and leprosy occur in higher frequency can be anticipated.

This work is supported in part by the National Institutes of Health (GCRC grant MO1RR00096).

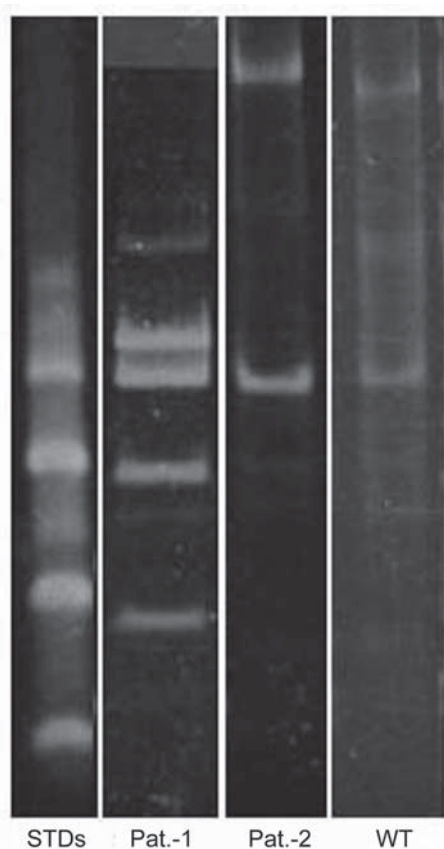


Figure. Polyacrylamide gel electrophoresis–restriction fragment length polymorphism of PCR amplicons digested with *Hae*III with standards. STDs, sexually transmitted diseases; Pat., patient; WT, wild type.

Frank Martiniuk,*¹
Shaline D. Rao,*¹
Thomas H. Rea,†
Michael S. Glickman,‡
Jerome Giovinazzo,§
William N. Rom,*
Aloys Cabrera,*
and William R. Levis*

*New York University School of Medicine, New York, New York, USA; †University of Southern California, Los Angeles, California, USA; ‡Memorial Sloan Kettering Cancer Center, New York, New York, USA; and §Amherst College, Amherst, Massachusetts, USA

References

1. Turk JL, Rees RJW. AIDS and leprosy. *Lepr Rev.* 1988;59:193–4.
2. Pustianowski AP, Lawn SD, Lockwood DNJ. Interactions between HIV infection and leprosy: a paradox. *Lancet Infect Dis.* 2006;6:350–60.
3. Lawn SD, Wood C, Lockwood DN. Borderline tuberculoid leprosy: an immune reconstitution phenomenon in a human immune deficiency virus-infected person. *Clin Infect Dis.* 2003;36:5–6.
4. Pereira GAS, Stefani GAS, Filho JAA, Souza LCS, Stefani GP, Martelli CMT. Human immunodeficiency virus type 1 (HIV-1) and *Mycobacterium leprae* co-infection: HIV-1 subtypes and clinical, immunologic, and histopathologic profiles in a Brazilian cohort. *Am J Trop Med Hyg.* 2004;71:679–84.
5. Visco-Comandini U, Longo B, Cuzzi T, Paglia MG, Antonucci G. Tuberculoid leprosy in a patient with AIDS: a manifestation of immune restoration syndrome. *Scand J Infect Dis.* 2004;36:881–3.
6. Lu PD, Patel M, Yosipovitch G, Martiniuk F, Cabrera A, Levis W. HIV and leprosy in the Eastern United States. *J Infect Dis.* 2005;192:1673–4.
7. Sharma NL, Mahajan VK, Sharma VC, Sarin S, Sharma RC. Erythema nodosum leprosum and HIV infection: a therapeutic experience. *Int J Lepr Other Mycobact Dis.* 2005;73:189–93.
8. Levis WR, Ernst JD. *Mycobacterium leprae* (leprosy, Hansen's disease). In: Mandell GL, Bennett JE, Dolin R, eds. *Mandell, Douglas, and Bennett's principles and practice of infectious diseases.* 6th ed., Vol. 2. New York: Elsevier/Churchill Livingstone; 2005. p. 2886–96.

¹These authors contributed equally to this article.

9. Martiniuk F, Tambini M, Rahimian J, Moreira A, Yee H, Tchou-Wong KM, et al. Identification of novel *Hsp65* RFLPs for *Mycobacterium leprae*. *J Drugs Dermatol*. 2007;6:268–74.
10. Frommel D, Teykle-Haimonot R, Verdie M, Negesse Y, Bulto T, Denis F. HIV infection and leprosy: a four-year survey in Ethiopia. *Lancet*. 1994;344:165–6.

Address for correspondence: William R. Levis, Department of Dermatology, NYU School of Medicine, Bellevue Hospital, 17-N-07, 1st Ave and 27th St, New York, NY 10016, USA; email: william_levis@yahoo.com

Endocarditis after Use of Tongue Scraper

To the Editor: Tongue scraping is advocated as a therapy for managing halitosis and as a technique for preventing dental caries by reducing bacterial counts in the mouth (1). The practice has been in existence for centuries (2). A Cochrane review has concluded that tongue cleaning is marginally and temporarily more effective than use of a toothbrush in reducing a measurable marker for halitosis, exhaled volatile sulfur compounds (3). The use of tongue scrapers may not be limited to those with clinical halitosis, as 10%–30% of Americans report bad breath (4), and websites offer to solve the problem of “your bad breath” for a price. We report the case of a woman in whom infective endocarditis followed the use of a tongue scraper.

A 59-year-old woman with a known history of mitral valve prolapse with associated valvular regurgitation had onset of progressive malaise, fever, sweats, myalgia, and headache; the symptoms lasted 10 days. Two months previously she had begun cleaning her tongue with a plastic tongue scraper purchased at her local pharmacy. She

had not undergone recent dental work. Her medical background included migraines, hypertension, mild quiescent psoriasis, and previous depression. Her medications were venlafaxine and candesartan.

When seen at her local hospital, she reported severe headache and myalgia, with fever. The same day, she had a rigor at home and reported chest tightness and mild dyspnea. Physical examination showed no focal findings other than the mitral valve prolapse. A provisional diagnosis of bacterial meningitis was made. Emergency treatment comprised intravenous dexamethasone, ceftriaxone, and benzylpenicillin. Cerebrospinal fluid analysis performed shortly after showed no cells and normal glucose and protein levels. Culture of the cerebrospinal fluid was negative. No further antimicrobial agents were administered. Multiple blood cultures were drawn but remained culture negative. Serologic tests for Q fever, *Bartonella* spp., and endemic rickettsiae were negative. She continued to be febrile.

A transthoracic echocardiogram showed dilatation of the mitral valve annulus with bi-leaflet prolapse and vegetation attached to the anterolateral commissure. She was referred to a tertiary care center, and therapy with penicillin, flucloxacillin, and gentamicin was begun for culture-negative endocarditis. Transesophageal echocardiography and visual examination at the time of valve replacement confirmed the presence of large valvular vegetations. After infected tissue was excised, a prosthetic mitral valve was placed. Extended culturing of the blood failed to identify a pathogen. Histopathologic examination of the explanted valve identified fibrinopurulent vegetations with destruction of the valve leaflet. The excised material was split into sections and submitted for culture; all demonstrated a scant growth of *Haemophilus parainfluenzae*. This finding was identified by a Remel Rapid NH Panel (Remel,

Lenexa, KS, USA) and confirmed by 16S rRNA gene sequencing. The patient was treated with ampicillin and gentamicin for 2 weeks. She then had 4 further weeks of therapy with daily ceftriaxone at home. She is now well.

This patient’s endocarditis was most likely caused by bacteremia from tongue scraping, and the abnormal valve is likely to have been a predisposing factor. The link between oral flora and endocarditis has long been recognized (5), and guidelines for prophylactic use of antimicrobial agents before dental manipulation are established. A literature review did not show any previous reports of endocarditis associated with use of a tongue scraper. There are numerous reports of endocarditis after tongue piercing, with a variety of organisms including viridans streptococci, *H. aphrophilus*, *Neisseria mucosa*, and methicillin-resistant *Staphylococcus aureus* (6–9). Most of these articles reported a pre-existing valvular abnormality, as in our case. Bacteremia caused by routine tooth brushing does not appear to be clinically important, and there are conflicting data about its frequency (10). The inoculum of bacteria transmitted into the bloodstream with brushing may be smaller than that with tooth extraction. Given the frequency of routine tooth brushing, antimicrobial prophylaxis is impractical in any case. The practice of tongue scraping, however, has not been well studied, and both the magnitude and frequency of bacteremia may be greater than with routine tooth brushing.

We propose that our patient’s infective endocarditis was most likely a consequence of bacteremia from her use of a tongue scraper. Persons with abnormal cardiac valves and intravascular devices such as pacemakers may be at particular risk. Patients with previous infective endocarditis and high-risk cardiac valve defects should be informed that tongue scraper use is not prudent.