

## Maculopathy in Dengue Fever

**To the Editor:** A recent article by Chlebicki et al (1) described 4 patients hospitalized for dengue fever who were found to have retinal hemorrhages. These patients reported reduced visual acuity and metamorphopsia, i.e., distorted visual images attributable to intrinsic retinal disease involving the macula; macular hemorrhages and exudates were found on retinal examination. The authors concluded that the retinal hemorrhages were responsible for the patients' visual symptoms.

This conclusion is misleading because retinal hemorrhages alone cause scotomas. Rather, the accumulation of subretinal fluid in the macula results in metamorphopsia and blurring of vision. In previous reports of patients in whom macular changes developed from dengue fever, some were found to have macular hemorrhages (2–4). In addition, clinical examination and investigation of these patients showed vasculopathic changes in the macular region that affected the retinal and choroidal blood vessels (5), although the tissues of the periphery tended to be spared. A fluorescein angiograph of the retina showed knobby hyperfluorescence of the retinal arterioles with minimal leakage, as well as some spots of leakage at the level of the retinal pigment epithelium. An indocyanine green angiograph showed diffuse hyperfluorescence of the choroid. These pathologic changes in the macula were the most likely cause of the blurring of vision in such patients, which has been the case in our experience.

The article by Chlebicki et al. did not state whether these procedures had been performed on their patients to confirm or exclude retinal or choroidal vasculopathy in the macula. Therefore, these authors would have had difficulty concluding that retinal hemorrhages caused blurring of

vision and metamorphopsia in patients with dengue maculopathy.

**Daniel Hsien-Wen Su\*  
and Soon-Phaik Chee\*†‡**

\*Singapore National Eye Centre, Singapore; †National University of Singapore, Singapore; and ‡Singapore Eye Research Institute, Singapore

### References

- Chlebicki MP, Ang B, Barkham T, Laude A. Retinal hemorrhages in 4 patients with dengue fever. *Emerg Infect Dis.* 2005;11:770–2.
- Wen KH, Sheu MM, Chung CB, Wang HZ, Chen CW. The ocular fundus findings in dengue fever [article in Chinese]. *Gaoxiong Yi Xue Ke Xue Za Zhi.* 1989;5:24–30.
- Haritoglou C, Scholz F, Bialasiewicz A, Klauss V. Ocular manifestations in dengue fever [article in German]. *Ophthalmologie.* 2000;97:433–6.
- Haritoglou C, Dotse SD, Rudolph G, Stephan CM, Thurau SR, Klauss V. A tourist with dengue fever and visual loss. *Lancet.* 2002;360:1070.
- Lim WK, Mathur R, Koh A, Yeoh R, Chee SP. Ocular manifestations of dengue fever. *Ophthalmology.* 2004;111:2057–64.

Address for correspondence: Daniel H-W. Su, Singapore National Eye Centre, 11 Third Hospital Ave, Singapore 168751; fax: 65-6226-3395; email: dannysu22@yahoo.com.sg

## Pulmonary Tuberculosis and SARS, China

**To the Editor:** As part of a cohort study of 83 patients with severe acute respiratory syndrome (SARS) in Beijing, China, we conducted a follow-up study of all the patients by routine medical examination. During the process, 3 patients with chest radiographs consistent with active disease were identified as having pulmonary tuberculosis (TB). Here we describe

the 1-year clinical outcome and immune response in these patients.

Demographic details and coexisting conditions are shown in the Table. Patient 1 was a healthcare worker who became infected with SARS-associated coronavirus (CoV) while on duty with SARS patients. After he was transferred to a hospital dedicated to SARS management, pulmonary TB was diagnosed (positive acid-fast bacilli smear on sputum samples). Patients 2 and 3 were known to have cases of pulmonary TB and became infected with SARS-CoV after contact with other patients hospitalized for SARS. These 2 patients were sputum smear-negative for acid-fast bacilli, and diagnosis was made on the basis of previous exposure to TB, relevant symptoms of typical pulmonary TB, chest radiographs consistent with active disease, a positive tuberculin skin test result, and the finding of cavity regression on chest radiographs after anti-TB treatment was initiated. No cultures were obtained for isolation and comparison of *Mycobacterium tuberculosis* strains (1). All 3 patients had confirmed SARS based on amplification of SARS-CoV RNA by reverse transcriptase-polymerase chain reaction (RT-PCR) from sputum and stool specimens (2). Patients 2 and 3 recovered without complications; patient 1 had the most severe disease and required mechanical ventilation in an intensive care unit before recovering.

Both cellular and humoral immunity were evaluated during the follow-up of these patients. T-lymphocyte subsets were measured 6 months after disease onset by flow cytometry using fluorescein isothiocyanate-labeled specific monoclonal antibodies. Compared to other SARS patients (n = 47), the 3 patients with TB had lower mean CD4+ T cells (368.4/μL vs. 656.6/μL, respectively; p = 0.05) and lower mean CD8+ T cells (371.0/μL vs. 490.1/μL, respectively; p = 0.39). SARS-CoV immunoglobulin

Table. Demographic and clinical information on severe acute respiratory syndrome (SARS) patients with pulmonary tuberculosis (TB), Beijing, China, 2003

Demographic/clinical characteristic	Patient 1	Patient 2	Patient 3
Sex	M	M	M
Age, y	48	18	20
Other coexisting conditions	<i>Pseudomonas aeruginosa</i> infection	None	None
Date of SARS onset	Apr 5, 2003	Apr 7, 2003	Apr 4, 2003
Date of TB diagnosis	Jun 12, 2003	Jan 24, 2003	Mar 5, 2003
Date of hospitalization or transfer to SARS ward	Apr 7, 2003	Apr 7, 2003	Apr 5, 2003
Leukocyte count at admission, / $\mu$ L	12,500	6,800	2,500
Total steroid dose used, mg	25,280	2,600	3,600
Intensive care unit admission	Yes	No	No
CD4/CD8 cell ratio 6 mo after disease	0.63	1.56	1.23
Absolute CD4 cell count 6 mo after disease, / $\mu$ L	368	431	306
Absolute lymphocyte count 6 mo after disease, / $\mu$ L	2,098	1,115	1,666

lin G (IgG) antibody titers were measured by enzyme-linked immunosorbent assay kit (Huada Company, Beijing, China) at months 1, 2, 3, 4, 7, 10, and 16 after disease onset. (Titers were not measured for the 3 TB patients at month 1.) Compared to most (26 [78.8%] of 33) other SARS patients whose antibodies remained detectable throughout follow-up, 2 of the 3 TB patients (patients 1 and 3) had undetectable antibody titers as of months 7 and 16, respectively. In patient 1, antibody titers, when detectable, were unusually low (40). Both patients 1 and 3 had prolonged viral excretion in stools, sputum, or both. While the median (range) duration of virus excretion in stools and sputa for the entire measurable cohort (n = 56) was 27 (16–127) and 21 (14–52) days, respectively (3), it was 125 and 16 days for patient 1, and 109 and 52 days for patient 3 (viral excretion data could not be obtained from patient 2 because sequential specimens for detection were unavailable).

TB in SARS patients has been reported on rare occasions (4,5). In a cohort of 236 patients in Singapore, it was diagnosed in 2 patients after recovery from SARS (4). As with patient 1 in this study, TB had developed after the patient acquired SARS, most likely as the result of reactivation of past infection or new infection with *M. tuberculosis*, while temporarily immunosuppressed because of

SARS (6) and corticoid therapy. Such phenomena have been described with other viral infections such as measles and HIV (7,8). By contrast, patients 2 and 3 were known TB patients who acquired SARS through exposure to SARS patients in the same hospital wards. Both diseases are known to be transiently immunosuppressive (6,9), and their combined effect resulted in more pronounced CD4+ cell decreases in coinfecting SARS patients than others. Such immunosuppression also resulted in poorer IgG antibody response in coinfecting SARS patients than in others and delayed viral clearance, as shown by longer viral excretion in sputum and stools. While viral excretion could be prolonged in coinfecting patients, no virus could be isolated from any RT-PCR-positive specimen collected after 6 weeks of illness, which suggests that excreted viruses were no longer infectious (3).

These case reports remind us of the importance of strict isolation of SARS patients, careful use of steroids for their case management, and the possibility of coinfection with TB in SARS patients with incomplete recovery.

This work was partly supported by the Programme de Recherche en Réseaux Franco-Chinois (P2R), the EC grant EPISARS (SP22-CT-2004-511063, SP22-CT-2004-003824), the National Institutes of Health CIPRA Project (NIH U19

AI51915), and the National 863 Program of China (2003AA208406, 2003AA208412C).

**Wei Liu,\* Arnaud Fontanet,†  
Pan-He Zhang,\* Lin Zhan,\*  
Zhong-Tao Xin,‡ Fang Tang,\*  
Laurence Baril,†  
and Wu-Chun Cao\***

\*Beijing Institute of Microbiology and Epidemiology, Beijing, People's Republic of China, †Institut Pasteur, Paris, France; and ‡Beijing Institute of Basic Medical Sciences, Beijing, People's Republic of China

## References

1. Crawford JT, Braden CR, Schable BA, Onorato ID. National Tuberculosis Genotyping and Surveillance Network: design and methods. *Emerg Infect Dis.* 2002;8:1192–6.
2. Revised U.S. surveillance case definition for severe acute respiratory syndrome (SARS) and update on SARS cases—United States and worldwide, December 2003. *MMWR Morb Mortal Wkly Rep.* 2003;52:1202–6.
3. Liu W, Tang F, Fontanet A, Zhan L, Zhao QM, Zhang PH, et al. Long-term SARS-coronavirus excretion from a patient cohort in China. *Emerg Infect Dis.* 2004;10:1841–3.
4. Low JGH, Lee CC, Leo YS. Severe acute respiratory syndrome and pulmonary tuberculosis. *Clin Infect Dis.* 2004;38:e123–5.
5. Centers for Disease Control and Prevention. Nosocomial transmission of *Mycobacterium tuberculosis* found through screening for severe acute respiratory syndrome—Taipei, Taiwan, 2003. *MMWR Morb Mortal Wkly Rep.* 2004;53:321–2.

6. Li T, Qiu Z, Zhang L, Han Y, He W, Liu Z, et al. Significant changes of peripheral T lymphocyte subsets in patients with severe acute respiratory syndrome. *J Infect Dis.* 2004;189:648–51.
7. Griffin DE, Bellini WJ. Measles. In: Fields BN, editor. *Virology*. New York: Raven Press; 1996. p. 1267–312.
8. Havlir DV, Barnes PF. Current concepts: tuberculosis in patients with human immunodeficiency virus infection. *N Engl J Med.* 1999;340:367–73.
9. Frieden TR, Sterling TR, Munsiff SS, Watt CJ, Dye C. Tuberculosis. *Lancet.* 2003;362:887–99.

Address for correspondence: Wu-Chun Cao, Beijing Institute of Microbiology and Epidemiology, State Key Laboratory of Pathogen and Biosecurity, Beijing, People's Republic of China; fax: 86-10-6389-6082; email: caowc@nic.bmi.ac.cn

## Tetanus in Injecting Drug Users, United Kingdom

**To the Editor:** The epidemiology of tetanus in the United Kingdom changed in 2003 when a cluster of cases in injecting drug users (IDUs) occurred (1,2). Before 2003, the incidence of tetanus was low in the United Kingdom, with occasional cases predominantly in unvaccinated elderly persons (3). The situation contrasted with the United States where injecting drug use is commonly reported among persons with tetanus (4).

We investigated the UK cluster to identify the source of infection and opportunities for prevention. We ascertained cases through statutory and nonstatutory reporting to the Health Protection Agency and collected additional information on IDUs for all reported cases of tetanus since

January 1, 2003, by adapting the existing enhanced tetanus surveillance. A case was defined as mild-to-moderate trismus and at least 1 of the following: spasticity, dysphagia, respiratory embarrassment, spasms, autonomic dysfunction, in a person who injected drugs in the month before symptom onset.

Twenty-five cases were reported from July 2003 to September 2004 (Figure). Thirteen (50%) were women; the median age of male and female patients was 39 and 32 years of age, respectively (range 20–53,  $p = 0.1$ ). Twenty patients were white, and 1 was Chinese (information was missing for 4). None reported travel overseas before becoming sick. Seventeen of 21 patients with information reported having injected heroin intramuscularly or subcutaneously (popping) or having missed veins. Most patients (16/25) came to the hospital with severe generalized tetanus. Injection site infections were common (17/19).

Two patients died (case fatality 8%). Of 23 survivors, 2 had mild disease and 21 required intensive treatment for a median of 40 days (range 24–65 in 15 cases with complete information). Tetanus immunization status available for 20 case-patients (based on medical records or patient and parental recall) indicated that only 1 patient (with severe disease) had received the 5 doses necessary for complete coverage. Nine patients were never vaccinated. Twelve of 14 patients tested for tetanus immunity on admission by a standard indirect enzyme-linked immunosorbent assay had antibody levels lower than the cutoff value for protection ( $<0.1$  IU/mL). One patient with severe disease had a level just above the cutoff value and 1 patient with mild disease had a protective antibody level. *Clostridium tetani* was isolated from 2 patients; tetanus toxin was detected in serum from 1 and also from another patient. Other anaerobes, including *C. novyi*, *C. histolyticum*, and *C. perfringens*, were

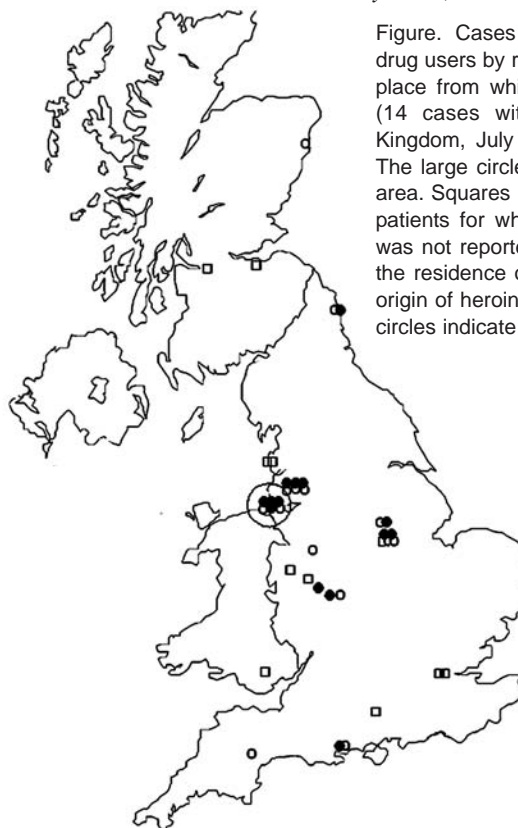


Figure. Cases of tetanus in injecting drug users by residence (25 cases) and place from which heroin was supplied (14 cases with information), United Kingdom, July 2003–September 2004. The large circle indicates the Liverpool area. Squares indicate the residence of patients for whom the origin of heroin was not reported, open circles indicate the residence of patients for whom the origin of heroin was reported, and solid circles indicate the origin of heroin.