

Nick Wilson,* Osman Mansoor,†
Douglas Lush,‡
and Tom Kiedrzyński§

*Otago University, Wellington, New Zealand; †Public Health Consulting Ltd, Wellington, New Zealand; ‡New Zealand Ministry of Health, Wellington, New Zealand; and §Secretariat of the Pacific Community, Noumea, New Caledonia

Address for correspondence: Nick Wilson, Department of Public Health, Wellington School of Medicine and Health Sciences, Otago University, PO Box 7343, Wellington South, New Zealand; fax: 64-4-4763646; email: nwilson@actrix.gen.nz

References

1. Herda PS. The 1918 influenza pandemic in Fiji, Tonga, and the Samoas. In: Bryder L, Dow DA, editors. New countries and old medicine: proceedings of an international conference on the history of medicine and health. Auckland (NZ): Pyramid Press; 1995. p. 46–53.
2. Crosby AW. America's forgotten pandemic: the influenza of 1918. Cambridge, UK: Cambridge University Press; 2003. p. 233–6.
3. Lazzari S, Stohr K. Avian influenza and influenza pandemics. Bull WHO. 2004;82:242.
4. Webster RG. Predictions for future human influenza pandemics. J Infect Dis. 1997;176:S14–9.
5. Madjid M, Lillibridge S, Mirhaji P, Casscells W. Influenza as a bioweapon. J R Soc Med. 2003;96:345–6.
6. Meltzer MI, Shoemaker HA, Kownaski M, Crosby R. FluAid 2.0: A manual to aid state and local-level public health officials plan, prepare, and practice for the next influenza pandemic (Beta test version). Atlanta: Centers for Disease Control and Prevention; 2000.
7. Secretariat of the Pacific Community Demography/Population Programme. Pacific Island populations 2004, prt 1. Available from <http://www.spc.org.nc/demog/English01-02/RecentStats/2004/Pacific%20Island%20Populations%202004.xls>
8. World Health Organization. The Work of WHO in the Western Pacific Region. Report of the regional director—1 July 2002–30 June 2003. Manila: The Organization; 2003:p. 217. [cited 2004 Jul 20]. Available from http://www.wpro.who.int/pdf/rcm54/en/rdr/19_stat_annex.pdf
9. World Health Organization. WHO consultation on priority public health interventions before and during an influenza pandemic. Geneva: The Organization; 2004. [cited 2004 Jul 20]. Available from http://www.who.int/csr/disease/avian_influenza/en/final.pdf
10. Glezen WP. Emerging infections: pandemic influenza. Epidemiol Rev. 1996;18:64–76.

Mycotic Brain Abscess Caused by Opportunistic Reptile Pathogen

To the Editor: A 38-year-old, HIV-seropositive Nigerian man sought treatment with an 8-month history of severe parietal headache, impaired memory, fatigue, paresthesia of the left arm, and left-sided focal seizures. He had no history of neurologic disorders, including epilepsy. On physical examination, the patient appeared well, alert, and oriented, with slurred speech. Evaluation of the visual fields showed left homonymous hemianopsia. All other neurologic assessments were unremarkable. The patient had a blood pressure of 120/80, a pulse of 88 beats per minute, and a body temperature of 37.3°C. Leukocyte count was 8,600/μL, total lymphocyte count was 1,981/μL, CD4+ cell count was 102/μL, and CD4/CD8 ratio was 0.07. HIV RNA-load was <50 copies/mL; all other laboratory parameters were normal. The patient had received anti-retroviral therapy (stavudine, lamivudine, nevirapine) for 5 months before admission, but no prophylaxis for opportunistic infections. Magnetic resonance imaging (MRI) of the brain disclosed 2 masses, 3.3 and 4.8 cm in diameter, respectively (Figure A), and signs of chronic sinusitis. A computed tomographic chest scan showed infiltration of both lower segments with multiple, small nodules (Figure B).

Blood cultures were repeatedly negative. A computer-guided needle-aspiration of the brain lesions yielded yellow-brown, creamy fluid in which abundant septated fungal hyphae were detected microscopically (Figure C). Cytologic investigation was consistent with a necrotic abscess. The cycloheximide-resistant isolate was strongly keratinolytic and identified as a *Chrysosporium* anamorph of *Nannizziopsis vriesii* (1,2). High-dose antimicrobial treatment with voriconazole (200 mg twice daily, subsequently reduced to 200 mg daily) was added to the antiretroviral (ritonavir, amprenavir, trizivir), anti-convulsive, and adjuvant corticosteroid treatment. The isolate was highly susceptible to voriconazole in vitro (MIC, ≤16μg/mL [Etest, AB-Biodisk Solna, Sweden]). Recovery was complicated by a generalized seizure and severe, acute psychosis associated with rapid refilling of the 2 lesions with mycotic abscess fluid. After re-aspiration, the patient's psychosis improved gradually, and no further seizures occurred. When last seen 4 months later, the patient was healthy and without neurologic deficits. His CD4+ cell count was 233/μL, HIV-load was <50 copies/mL, and a MRI scan of the brain showed partial regression of the 2 brain lesions (Figure D).

Chrysosporium spp. are common soil saprobes, occasionally isolated from human skin. Invasive infection is very rare in humans, and most were observed in immunocompromised patients, manifesting as osteomyelitis (3,4) or diffuse vascular brain invasion (5). Here, we report the first case of brain abscesses by the *Chrysosporium* anamorph of *N. vriesii*. This fungus has been associated with fatal mycosis in reptiles (6,7) and cutaneous mycosis in chameleons originating from Africa (2).

In our patient, we were unable to determine the portal of entry and the sequence of fungal dissemination; no

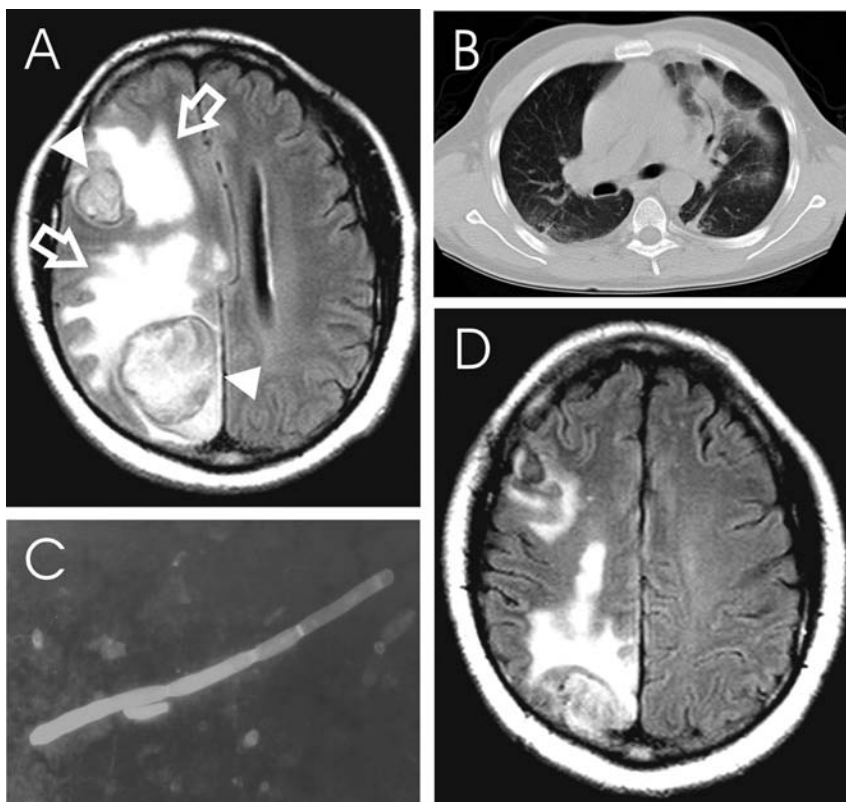


Figure. *Chrysosporium* sp. brain abscess in an HIV-seropositive patient. A) T2-weighted magnetic resonance imaging (MRI) scan of the brain showing 2 large masses (triangles) surrounded by a ring of signal intensity and extensive perifocal edema (open arrows), global swelling of the right hemisphere, and a midline shift of 1.2 cm. B) Computed tomographic scan of the chest showing infiltration of the left and right lower segment. C) Mold mycelium in aspirate of brain abscess with calcoflour white stain. D) T2-weighted MRI scan of the brain performed 4 months after beginning of therapy.

skin lesions were present at the time of admission. However, the multifocal nature, lung infiltration, and involvement of the middle cerebral artery distribution suggest hematogenous dissemination (8,9) after replication of airborne conidia within the respiratory tract.

Fungi cause >90% of brain abscesses in immunocompromised transplant patients with an associated mortality rate of 97% (10), despite aggressive surgery and antifungal therapy (9). Our patient was treated successfully with abscess drainage, antiretroviral therapy, and oral voriconazole, a novel antifungal triazole drug. Despite limited data available on voriconazole penetration into brain abscess cavities (9), this drug

was clinically and radiologically effective in our patient.

Acknowledgments

We thank the patient for cooperating with our investigation, Pfizer Germany for providing voriconazole, and Heidemarie Losert and Elisabeth Antweiler for their excellent technical assistance.

Christoph Steininger,*
Jan van Lunzen,*
Kathrin Tintelnot,†
Ingo Sobottka,* Holger Rohde,*
Matthias Ansvor Horstkotte,*
and Hans-Jürgen Stellbrink*

*University Clinic Eppendorf, Hamburg, Germany; and †Robert Koch-Institut, Mykologie, Berlin, Germany

References

1. Van Oorschot CAN. A revision of *Chrysosporium* and allied genera. *Stud Mycol.* 1980;1:89.
2. Pare JA, Sigler L, Hunter DB, Summerbell RC, Smith DA, Machin KL. Cutaneous mycoses in chameleons caused by the *Chrysosporium* anamorph of *Nannizziopsis vriesii* (Apinis) Currah. *J Zoo Wildl Med.* 1997;28:443-53.
3. Stillwell WT, Rubin BD, Axelrod JL. *Chrysosporium*, a new causative agent in osteomyelitis. A case report. *Clin Orthop.* 1984;190-2.
4. Roilides E, Sigler L, Bibashi E, Katsifa H, Flaris N, Panteliadis C. Disseminated infection due to *Chrysosporium zonatum* in a patient with chronic granulomatous disease and review of non-aspergillus fungal infections in patients with this disease. *J Clin Microbiol.* 1999;37:18-25.
5. Warwick A, Ferrieri P, Burke B, Blazar BR. Presumptive invasive *Chrysosporium* infection in a bone marrow transplant recipient. *Bone Marrow Transplant.* 1991;8:319-22.
6. Nichols DK, Weyant RS, Lamirande EW, Sigler L, Mason RT. Fatal mycotic dermatitis in captive brown tree snakes (*Boiga irregularis*). *J Zoo Wildl Med.* 1999;30:111-8.
7. Thomas AD, Sigler L, Peucker S, Norton JH, Nielan A. *Chrysosporium* anamorph of *Nannizziopsis vriesii* associated with fatal cutaneous mycoses in the salt-water crocodile (*Crocodylus porosus*). *Med Mycol.* 2002;40:143-51.
8. Calfee DP, Wispelwey B. Brain abscess. *Semin Neurol.* 2000;20:353-60.
9. Mathisen GE, Johnson JP. Brain abscess. *Clin Infect Dis.* 1997;25:763-79.
10. Hagensee ME, Bauwens JE, Kjos B, Bowden RA. Brain abscess following marrow transplantation: experience at the Fred Hutchinson Cancer Research Center, 1984-1992. *Clin Infect Dis.* 1994;19:402-8.

Address for correspondence: Christoph Steininger, University Clinic Eppendorf, Department of Medicine I, Infectious Diseases Unit, Martinistrasse 52, 20246 Hamburg, Germany; fax: 49-40-42803-6832; email: c.steininger@uke.uni-hamburg.de

The opinions expressed by authors contributing to this journal do not necessarily reflect the opinions of the Centers for Disease Control and Prevention or the institutions with which the authors are affiliated.