



HHS Public Access

Author manuscript

N Engl J Med. Author manuscript; available in PMC 2024 March 28.

Published in final edited form as:

N Engl J Med. 2012 September 13; 367(11): 1020–1024. doi:10.1056/NEJMoa1205114.

Outbreak of *Mycobacterium chelonae* Infection Associated with Tattoo Ink

Byron S. Kennedy, M.D., Ph.D., M.P.H.,

Brenden Bedard, M.P.H.,

Mary Younge, R.N.,

Deborah Tuttle, R.N., M.P.S.,

Eric Ammerman, B.S.,

John Ricci, M.S.,

Andrew S. Doniger, M.D., M.P.H.,

Vincent E. Escuyer, Ph.D.,

Kara Mitchell, Ph.D.,

Judith A. Noble-Wang, Ph.D.,

Heather A. O’Connell, Ph.D.,

William A. Lanier, D.V.M., M.P.H.,

Linda M. Katz, M.D., M.P.H.,

Robert F. Betts, M.D.,

Mary Gail Mercurio, M.D.,

Glynis A. Scott, M.D.,

Matthew A. Lewis, M.D.,

Mark H. Goldgeier, M.D.

Monroe County Department of Public Health, Rochester (B.S.K., B.B., M.Y., D.T., E.A., J.R., A.S.D.), the New York State Department of Health, Albany (V.E.E., K.M.), the University of Rochester Medical Center, Rochester (R.F.B., M.G.M., G.A.S., M.A.L.), and Clinton Crossings Dermatology, Rochester (M.H.G.) — all in New York; the Centers for Disease Control and Prevention, Atlanta (J.A.N.-W., H.A.O.); and the Food and Drug Administration, College Park, MD (W.A.L., L.M.K.)

Abstract

BACKGROUND—In January 2012, on the basis of an initial report from a dermatologist, we began to investigate an outbreak of tattoo-associated *Mycobacterium chelonae* skin and soft-tissue infections in Rochester, New York. The main goals were to identify the extent, cause, and form of transmission of the outbreak and to prevent further cases of infection.

Address reprint requests to Dr. Kennedy at the Monroe County Department of Public Health, 111 Westfall Rd., Rm. 950, Rochester, NY 14620, or at bkennedy@monroecounty.gov.

The findings and conclusions in this report are those of the authors and do not necessarily represent the official position of the Centers for Disease Control and Prevention or the Agency for Toxic Substances and Disease Registry.

Disclosure forms provided by the authors are available with the full text of this article at NEJM.org.

METHODS—We analyzed data from structured interviews with the patients, histopathological testing of skin-biopsy specimens, acid-fast bacilli smears, and microbial cultures and antimicrobial susceptibility testing. We also performed DNA sequencing, pulsed-field gel electrophoresis (PFGE), cultures of the ink and ingredients used in the preparation and packaging of the ink, assessment of source water and faucets at tattoo parlors, and investigation of the ink manufacturer.

RESULTS—Between October and December 2011, a persistent, raised, erythematous rash in the tattoo area developed in 19 persons (13 men and 6 women) within 3 weeks after they received a tattoo from a single artist who used premixed gray ink; the highest occurrence of tattooing and rash onset was in November (accounting for 15 and 12 patients, respectively). The average age of the patients was 35 years (range, 18 to 48). Skin-biopsy specimens, obtained from 17 patients, showed abnormalities in all 17, with *M. chelonae* isolated from 14 and confirmed by means of DNA sequencing. PFGE analysis showed indistinguishable patterns in 11 clinical isolates and one of three unopened bottles of premixed ink. Eighteen of the 19 patients were treated with appropriate antibiotics, and their condition improved.

CONCLUSIONS—The premixed ink was the common source of infection in this outbreak. These findings led to a recall by the manufacturer.

SINCE 2003, A GROWING NUMBER OF Published case reports have linked tattooing with localized infections due to atypical mycobacteria.^{1–13} *Mycobacterium chelonae* is a rapidly growing form of nontuberculous mycobacteria; overall, it is an uncommon cause of cutaneous infections.¹⁴ We describe an investigation of an outbreak involving 19 persons with presumed *M. chelonae* infection after receiving a tattoo from a single artist who used a premixed ink that was contaminated before distribution. Previous outbreaks were associated with dilution and contamination of ink at the tattoo parlor.

METHODS

INDEX PATIENT

On January 4, 2012, we and colleagues at the Monroe County Department of Public Health began investigating an outbreak on the basis of a report from a dermatologist of the development of a persistent granulomatous rash on the arm of a person who had received a tattoo on that area in October 2011. This index patient was a previously healthy 20-year-old man who had a history of multiple tattoos without any health problems. He was treated unsuccessfully with glucocorticoids by his primary care provider before being referred to a dermatologist. Histopathological examination and culture of a biopsy specimen confirmed the presence of *M. chelonae*.

EPIDEMIOLOGIC INVESTIGATION

After the interview with the index patient, investigators at the Monroe County Department of Public Health learned that similar reactions had developed in other persons who had obtained tattoos from the same artist at the same tattoo parlor. During a site visit, investigators interviewed the tattoo artist and learned that since May 2011, he had been using a new, hand-blended, diluted black ink (gray wash) that contained pigment, distilled water, witch hazel, and glycerin. Gray wash is used to achieve shading and a three-

dimensional quality in tattoos; it is a prominent component of portrait and photography tattoos, which are currently popular.

According to the artist, the manufacturer diluted the black ink with distilled water before packaging and shipping the ink. This premixed ink was prepackaged in three dilution strengths per set: a 30%, or light, wash (i.e., greatest dilution); a 60%, or medium, wash (i.e., intermediate dilution); and a 90%, or dark, wash (i.e., least dilution). The tattoo artist originally purchased the ink in April 2011 at a tattoo trade show in Arizona, and he later ordered an additional supply. The product labeling contained no lot number or other unique manufacturing identification. He stopped using the premixed ink in December 2011.

To identify cases of infection, a number of steps were taken. First, a regional pathology laboratory used by many dermatologists was alerted to report any cases of ink-associated granulomatous reactions. Second, a list of patrons who were tattooed between May and December 2011 was obtained from the tattoo artist. The artist did not maintain detailed records that included the type of ink that was used with each patron. Third, all local tattoo parlors within Monroe County were identified, contacted by telephone, and queried about ink products used in their establishments as well as any reports of rashlike illnesses. No other parlor used this premixed ink, and no rashlike illnesses were reported. Finally, exposed patrons were contacted by telephone and interviewed, with the use of a standard questionnaire, about receiving a tattoo and any subsequent rashlike illness.

An environmental health assessment suggested that best practices were generally observed at the parlor where the index patient received his tattoo, and no concerns about hygiene were noted. In particular, the artists used sterile instruments, wore clean disposable gloves, poured ink into single-use containers, and provided appropriate aftercare to the tattooed site. Importantly, no dilution or mixing of inks at the parlor occurred, and the artist avoided contamination of ink from tap water at the facility. These practices were confirmed by all interviewed patrons.

The Food and Drug Administration (FDA) inspected the Arizona-based manufacturer and distributor of the ink. The FDA collected samples of ink and of the ingredients used in its preparation and packaging, and the Centers for Disease Control and Prevention (CDC) cultured them.

The clinical findings in all but two patients were evaluated at the University of Rochester Medical Center; of the two patients with findings that were not evaluated, one had follow-up in another state and another declined evaluation and treatment. Patients were evaluated by dermatologists, who performed skin biopsies of the tattooed lesions; tissue specimens were then sent for histologic and microbiologic analysis. Patients were referred to an infectious-disease expert for follow-up care and offered empirical treatment with appropriate antimicrobial agents.

HISTOLOGIC AND MICROBIOLOGIC INVESTIGATION

Laboratory investigations were conducted at the University of Rochester Medical Center, the Wadsworth Center of the New York State Department of Health, and the CDC. Samples

from clinical isolates, one opened bottle of 60% premixed gray ink wash and three unopened bottles (one containing 30% wash, one containing 60% wash, and one containing 90% wash), and water and swabs from faucets (biofilm) were submitted for various microbiologic tests, including acid-fast bacilli smears, cultures and antimicrobial sensitivity profiles, DNA sequencing, and pulsed-field gel electrophoresis (PFGE), according to standard protocols.^{15–20}

RESULTS

EPIDEMIOLOGIC INVESTIGATION

In this outbreak of *M. chelonae* infections associated with tattoos, 19 cases were identified: 14 confirmed cases, 4 probable cases, and 1 suspected case (see Table S1 in the Supplementary Appendix, available with the full text of this article at NEJM.org). On the basis of a list of 167 patrons provided by the tattoo artist, the attack rate increased from zero during the period from May through August to a peak of 65% in November (Fig. 1). Rashes were confined to areas of the skin tattooed with the premixed gray ink (Fig. 2). The average age of the 13 men and 6 women with *M. chelonae* infection was 35 years (range, 18 to 48).

HISTOLOGIC AND MICROBIOLOGIC INVESTIGATION

Biopsy specimens were obtained from 17 of the 19 patients: sparse lymphohistiocytic infiltrates in the upper dermis were observed in 12 specimens, granulomas in 5, and acid-fast organisms in 2 (Fig. S1 in the Supplementary Appendix). *M. chelonae* was isolated in 14 of the 17 tissue specimens and confirmed by DNA sequencing.

Antimicrobial susceptibility studies for atypical mycobacteria are not routinely performed in the United States; however, these studies were performed in two patients. In the first patient, *M. chelonae* was sensitive to clarithromycin, doxycycline, and linezolid; had intermediate sensitivity to ciprofloxacin; and was resistant to ceftiofur. In the second patient, *M. chelonae* was sensitive to clarithromycin and doxycycline, had intermediate sensitivity to linezolid, and was resistant to ciprofloxacin and ceftiofur.

The CDC results confirmed the isolation of *M. chelonae* and showed an indistinguishable PFGE pattern in 11 clinical isolates and one of three unopened bottles of ink (i.e., the 30% gray wash) (Fig. S2 in the Supplementary Appendix). *M. chelonae* was not isolated from the water or faucet in the tattoo parlor.

INFECTION-CONTROL MEASURES

We collected the remaining bottles of premixed ink from the tattoo parlor. We also provided information and education to both tattoo artists and patrons at a large tattoo trade show hosted in Rochester, New York. The materials provided included information on New York State law, which bans tattooing of persons younger than 18 years of age, regardless of whether parental consent is given; tattooing best practices, including the use of sterile products and aseptic techniques as well as appropriate aftercare; risks associated with tattooing; signs of a reaction from a tattoo; and steps to be taken if a reaction to a tattoo occurs.

The CDC issued a nationwide alert about the outbreak. The manufacturer voluntarily recalled the ink. Appropriate antimicrobial therapy (macrolides at first, based on the recommendations from relevant prior case reports, and then macrolides, doxycycline, or both, once sensitivities were available) was initiated in 18 of the 19 patients, and their condition improved, although the speed of recovery in each patient varied.

DISCUSSION

In this outbreak in Rochester, New York, cutaneous *M. chelonae* infection developed in 19 patrons of a tattoo parlor, with culture confirmation in 14, after tattooing performed with the use of a premixed gray ink manufactured in Arizona. The epidemiologic, histologic, and microbiologic evidence implicated the ink, not the practices of the tattoo parlor, as the common source of infection.

Previous studies have linked *M. chelonae* to other procedures.^{20–24} However, only in the past decade have cutaneous infections with nontuberculous mycobacteria been associated with tattooing, with Wolf and Wolf describing the first case in 2003.¹ According to their report, cultures were negative, but polymerase-chain-reaction analysis confirmed the diagnosis; they were unable to confirm the mycobacterial species. Goldman et al. reported on a case series involving 48 patients with *M. chelonae* infections linked to tattooing in France.⁵ In that outbreak, *M. chelonae* was isolated in 13 patients; no PFGE analysis was performed. *M. chelonae* was isolated from opened, but not unopened, bottles of ink. In the United States, Drage et al. described an outbreak of *M. chelonae* infections involving 6 patients with tattoos.⁴ In that case series, cultures confirmed *M. chelonae* infection in 3 patients.

Previous studies, although not testing specifically for mycobacteria, have shown that unopened stock bottles of tattoo ink may contain bacteria that are pathogenic in humans despite claims of sterility.²⁵ In the current study, mycobacteria were detected in both opened and unopened bottles of ink. These findings suggest that mycobacteria may be another potential contaminant, especially if the ink is diluted with nonsterile water before distribution.

A major limitation of this investigation was the lack of detailed records on the patrons of the tattoo parlor, which affected the assessment of exposure. The tattoo artist was uncertain about which patron received which batch of ink and about the dilution of the premixed gray ink used. It seems reasonable to suppose that the first batch was used during the earlier exposure period, since no cases of infection developed until October; this suggests that only the second batch was contaminated. The likelihood of overlooked cases was minimized through the active surveillance efforts undertaken by the public health department.

Our findings have at least two implications. First, since tattooing has become more popular over time, the incidence of cutaneous mycobacterial infections may be underestimated, given the lack of both routine testing and mandated reporting. Second, although contamination in tattoo parlors has been implicated in previous outbreaks, our investigation of this outbreak shows that premixed ink contaminated before distribution poses a risk to

public health, which may suggest the need for enhanced oversight of not just tattooing but also the inks used in tattooing to ensure public safety.

Supplementary Material

Refer to Web version on PubMed Central for supplementary material.

Acknowledgments

We thank Greg Beyler, Christopher Cecere, Wanda Parker, L.P.N., Anita Weimer, R.N., B.S.N., Donna Hubbard, Shaun Sharp, Natalie Schubel, Samantha Bonacci, and Liz Kwon, M.D., M.P.H., at the Monroe County Department of Public Health; Bette Jensen, Nadege Toney, and Margaret Williams at the CDC; staff members of the Office of Regulatory Affairs, the Office of Cosmetics and Colors, and the Coordinated Outbreak Response and Evaluation Network of the FDA; Elizabeth Arthur, M.D., at the University of Rochester Medical Center; and Patrick Condry, M.D., of Greece Dermatology Associates.

References

1. Wolf R, Wolf D. A tattooed butterfly as a vector of atypical Mycobacteria. *J Am Acad Dermatol.* 2003; 48 (Suppl) S73–S74. [PubMed: 12734482]
2. Kluger N, Muller C, Gral N. Atypical mycobacteria infection following tattooing: review of an outbreak in 8 patients in a French tattoo parlor. *Arch Dermatol.* 2008; 144: 941–2. [PubMed: 18645149]
3. Preda VA, Maley M, Sullivan JR. *Mycobacterium chelonae* infection in a tattoo site. *Med J Aust.* 2009; 190: 278–79. [PubMed: 19296796]
4. Drage LA, Ecker PM, Orenstein R, Phillips PK, Edson RS. An outbreak of *Mycobacterium chelonae* infections in tattoos. *J Am Acad Dermatol.* 2010; 62: 501–6. [PubMed: 19733936]
5. Goldman J, Caron F, de Quatrebarbes J, et al. Infections from tattooing: outbreak of *Mycobacterium chelonae* in France. *BMJ.* 2010; 341: c5483. [PubMed: 20978041]
6. Bechara C, Macheras E, Heym B, Pages A, Auffret N. *Mycobacterium abscessus* skin infection after tattooing: first case report and review of the literature. *Dermatology.* 2010; 221: 1–4.
7. Ricciardo B, Weedon D, Butler G. *Mycobacterium abscessus* infection complicating a professional tattoo. *Australas J Dermatol.* 2010; 51: 287–9. [PubMed: 21198529]
8. Kay MK, Perti TR, Duchin JS. Tattoo-associated *Mycobacterium haemophilum* skin infection in immunocompetent adult, 2009. *Emerg Infect Dis.* 2011; 17: 1734–6. [PubMed: 21888807]
9. Hamsch C, Hartschuh W, Enk A, Flux K. A Chinese tattoo paint as a vector of atypical mycobacteria-outbreak in 7 patients in Germany. *Acta Derm Venereol.* 2011; 91: 63–4. [PubMed: 21103853]
10. Kappel S, Cotliar J. Inoculation of *Mycobacterium chelonae* from a tattoo. *J Am Acad Dermatol.* 2011; 64: 998–9. [PubMed: 21496711]
11. Rodríguez-Blanco I, Fernández LC, Suárez-Peñaranda JMS, Pérez del Molino ML, Esteban J, Almagro M. *Mycobacterium chelonae* infection associated with tattoos. *Acta Derm Venereol.* 2011; 91: 61–2. [PubMed: 21264454]
12. Mitchell CB, Isenstein A, Burkhart CN, Groben P, Morrell DS. Infection with *Mycobacterium immunogenium* following a tattoo. *J Am Acad Dermatol.* 2011; 64 (5) e70–e71. [PubMed: 21496684]
13. Bini I, Jankovi A, Ljubenovi M, Gligorijevi J, Jan i S, Jankovi D. *Mycobacterium chelonae* infection due to a black tattoo ink dilution. *Am J Clin Dermatol.* 2011; 12: 404–6. [PubMed: 21797287]
14. Hay RJ. *Mycobacterium chelonae* — a growing problem in soft tissue infection. *Curr Opin Infect Dis.* 2009; 22: 99–101. [PubMed: 19276876]
15. Brown-Elliott BA, Wallace RJ Jr. Clinical and taxonomic status of pathogenic nonpigmented or late-pigmenting rapidly growing mycobacteria. *Clin Microbiol Rev.* 2002; 15: 716–46. [PubMed: 12364376]

16. Martin A, Uwizeye C, Fissette K, et al. Application of the hsp65 PRA method for the rapid identification of mycobacteria isolated from clinical samples in Belgium. *J Microbiol Methods*. 2007; 71: 39–43. [PubMed: 17719666]
17. Adékambi T, Colson P, Drancourt M. rpoB-based identification of nonpigmented and late-pigmenting rapidly growing mycobacteria. *J Clin Microbiol*. 2003; 41: 5699–708. [PubMed: 14662964]
18. Vanitha JD, Venkatasubramani R, Dharmalingam K, Paramasivan CN. Large-restriction-fragment polymorphism analysis of *Mycobacterium chelonae* and *Mycobacterium terrae* isolates. *Appl Environ Microbiol*. 2003; 69: 4337–41. [PubMed: 12839827]
19. Wallace RJ Jr, Zhang Y, Brown BA, Fraser V, Mazurek GH, Maloney S. DNA large restriction fragment patterns of sporadic and epidemic nosocomial strains of *Mycobacterium chelonae* and *Mycobacterium abscessus*. *J Clin Microbiol*. 1993; 31: 2697–701. [PubMed: 8253968]
20. Tenover FC, Arbeit RD, Goering RV, et al. Interpreting chromosomal DNA restriction patterns produced by pulse-field gel electrophoresis: criteria for bacterial strain typing. *J Clin Microbiol*. 1995; 33: 2233–9. [PubMed: 7494007]
21. Safranek TJ, Jarvis WR, Carson LA, et al. *Mycobacterium chelonae* wound infections after plastic surgery employing contaminated gentian violet skin-marking solution. *N Engl J Med*. 1987; 317: 197–201. [PubMed: 3600710]
22. Wenger JD, Spika JS, Smithwick RW, et al. Outbreak of *Mycobacterium chelonae* infection associated with use of jet injectors. *JAMA*. 1990; 264: 373–6. [PubMed: 2362334]
23. Winthrop KL, Abrams M, Yakrus M, et al. An outbreak of mycobacterial furunculosis associated with footbaths at a nail salon. *N Engl J Med*. 2002; 346: 1366–71. [PubMed: 11986410]
24. Meyers H, Brown-Elliott BA, Moore D, et al. An outbreak of *Mycobacterium chelonae* infection following liposuction. *Clin Infect Dis*. 2002; 34: 1500–7. [PubMed: 12015697]
25. Høgsberg T, Saunte DM, Frimodt-Møller N, Serup J. Microbial status and product labeling of 58 original tattoo inks. *J Eur Acad Dermatol Venereol*. 2011. December 7.

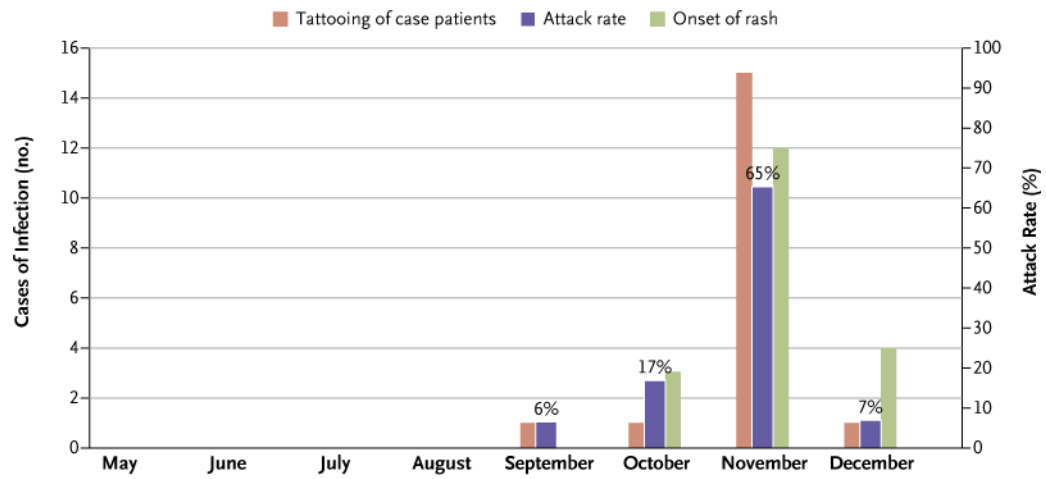


Figure 1. Epidemic Curve for Tattoo-Associated Infections and Attack Rate among 167 Patrons of a Tattoo Parlor, According to Month of Occurrence, 2011

The onset of the rash occurred 1 to 3 weeks after receipt of the tattoo. In one case, tattooing occurred in September or October and the rash began in October.

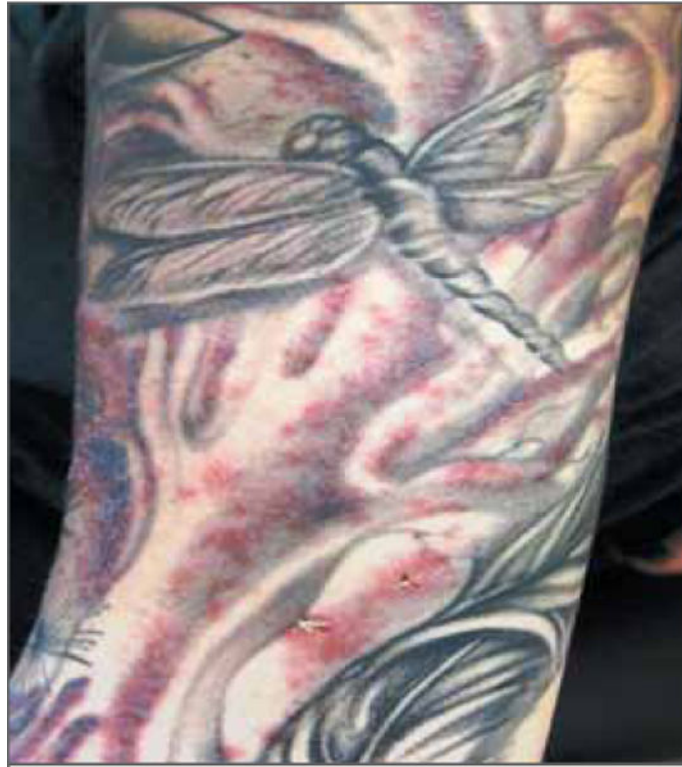

Figure 2.
Typical Rash Associated with *Mycobacterium chelonae* Infection.