

# *Nocardia pseudobrasiliensis* Co-infection in SARS-CoV-2 Patients

Daniel Beau Stamos, Aldo Barajas-Ochoa, Jillian E. Raybould



## Medscape CME Activity

In support of improving patient care, this activity has been planned and implemented by Medscape, LLC and Emerging Infectious Diseases. Medscape, LLC is jointly accredited with commendation by the Accreditation Council for Continuing Medical Education (ACCME), the Accreditation Council for Pharmacy Education (ACPE), and the American Nurses Credentialing Center (ANCC), to provide continuing education for the healthcare team.

Medscape, LLC designates this Journal-based CME activity for a maximum of 1.00 **AMA PRA Category 1 Credit(s)**<sup>™</sup>. Physicians should claim only the credit commensurate with the extent of their participation in the activity.

Successful completion of this CME activity, which includes participation in the evaluation component, enables the participant to earn up to 1.0 MOC points in the American Board of Internal Medicine's (ABIM) Maintenance of Certification (MOC) program. Participants will earn MOC points equivalent to the amount of CME credits claimed for the activity. It is the CME activity provider's responsibility to submit participant completion information to ACCME for the purpose of granting ABIM MOC credit.

All other clinicians completing this activity will be issued a certificate of participation. To participate in this journal CME activity: (1) review the learning objectives and author disclosures; (2) study the education content; (3) take the post-test with a 75% minimum passing score and complete the evaluation at <http://www.medscape.org/journal/eid>; and (4) view/print certificate. For CME questions, see page 875.

**Release date: March 22, 2023; Expiration date: March 22, 2024**

### Learning Objectives

Upon completion of this activity, participants will be able to:

- Determine the clinical features and predisposing factors for nocardiosis and COVID-19 coinfection, based on a case report of SARS-CoV-2 coinfection with pulmonary *Nocardia pseudobrasiliensis* and a literature review
- Assess the course and treatment of nocardiosis and COVID-19 coinfection, based on a case report of SARS-CoV-2 coinfection with pulmonary *Nocardia pseudobrasiliensis* and a literature review
- Evaluate the clinical implications of the features, course, treatment, and predisposing factors for nocardiosis and COVID-19 coinfection, based on a case report of SARS-CoV-2 coinfection with pulmonary *Nocardia pseudobrasiliensis* and a literature review

### CME Editor

**Dana C. Dolan, BS**, Technical Writer/Editor, Emerging Infectious Diseases. *Disclosure: Dana C. Dolan, BS, has no relevant financial relationships.*

### CME Author

**Laurie Barclay, MD**, freelance writer and reviewer, Medscape, LLC. *Disclosure: Laurie Barclay, MD, has no relevant financial relationships.*

### Authors

**Daniel Beau Stamos, BS; Aldo Barajas-Ochoa, MD; and Jillian E. Raybould, MD.**

Author affiliation: Virginia Commonwealth University Health System, Richmond, Virginia, USA.

DOI: <https://doi.org/10.3201/eid2904.221439>

During the SARS-CoV-2 pandemic, few cases of *Nocardia* spp. co-infection have been reported during or after a COVID-19 infection. *Nocardia* spp. are gram-positive aerobic actinomycetes that stain partially acid-fast, can infect immunocompromised patients, and may cause disseminated disease. We present the case of a 52-year-old immunocompromised man who developed *Nocardia pseudobrasiliensis* pneumonia after a SARS-CoV-2 infection, and we summarize the current literature for nocardiosis and SARS-CoV-2 co-infections. *Nocardia* spp. infection should remain on the differential diagnosis of pneumonia in immunocompromised hosts, regardless of other co-infections. Sulfonamide–carbapenem combinations are used as empiric therapy for nocardiosis; species identification and susceptibility testing are required to select the optimal treatment for each patient.

*Nocardia pseudobrasiliensis* are gram-positive aerobic actinomycetes; stains of *N. pseudobrasiliensis* are partially acid fast (1). As with other *Nocardia* species, *N. pseudobrasiliensis* can infect immunocompromised patients and may cause disseminated disease (2). Risk factors for nocardiosis include immunosuppression caused by solid organ or hematopoietic cell transplantation, glucocorticoid therapy, chronic lung disease, diabetes, AIDS, and malignancy (3,4). Infection by other pathogens during or after SARS-CoV-2 infection is a known but relatively uncommon occurrence. Nocardiosis co-infection with SARS-CoV-2 is rarely reported. We describe a case of SARS-CoV-2 co-infection with pulmonary *Nocardia pseudobrasiliensis* and summarize the literature on nocardiosis and COVID-19 co-infection.

### Case Report

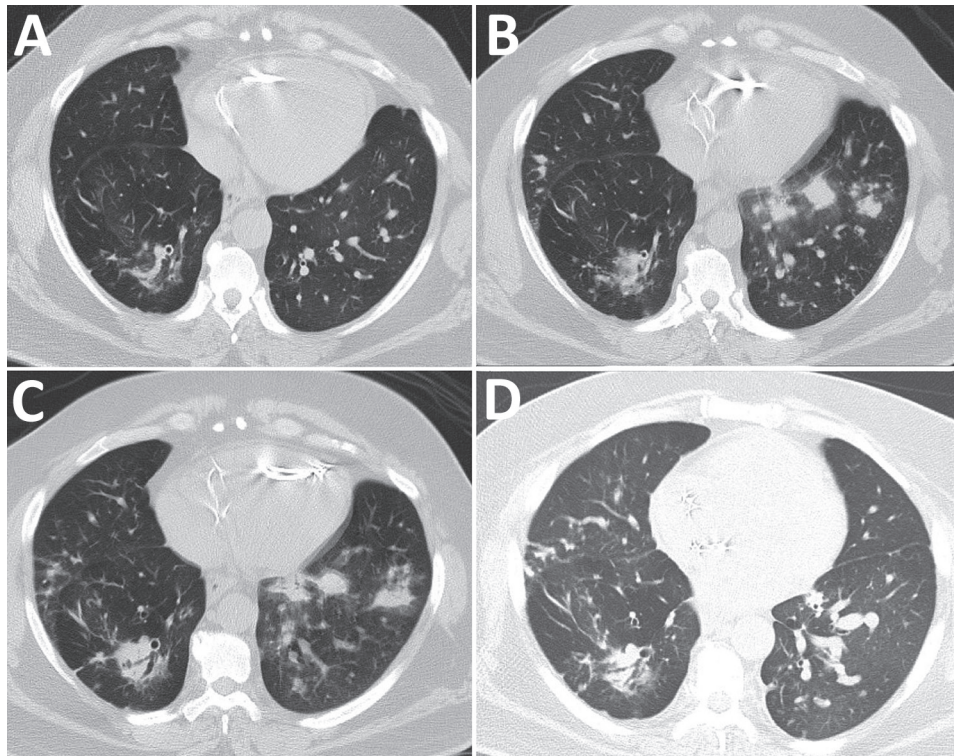
A 52-year-old man sought care at the emergency department at Virginia Commonwealth University Health System (Richmond, Virginia, USA) in July 2022 because of increased work of breathing after a positive home COVID-19 test. The patient's symptoms began 10 days before admission. He reported that he had not experienced fevers, chills, sore throat, abdominal pain, or diarrhea. He was admitted for the management of hypoxia caused by COVID-19 pneumonia. His medical history included type 2 diabetes mellitus treated with empagliflozin, bronchiectasis, and multisystem sarcoidosis. His sarcoidosis was first diagnosed in 2011 by lung biopsy and had progressed to stage IV pulmonary sarcoidosis by 2019. An implantable cardioverter defibrillator was placed in 2019 to address cardiac sarcoidosis. For his sarcoidosis, the patient received oral hydroxychloroquine (200 mg 2×/d) and intravenous (IV) infliximab (800 mg every 8 wk). He was a former smoker who stopped 30 years earlier; he had a job as an apartment maintenance worker.

At the time of admission, the patient was hemodynamically stable and afebrile. Pertinent physical examination findings included increased work of breathing and wheezing. Cardiac and pulmonary examination were otherwise unremarkable. Chest radiograph showed findings related to sarcoidosis without acute cardiopulmonary disease. On hospital day 1, he started COVID-19 treatment with intravenous remdesivir (200 mg/d) and dexamethasone (6 mg/d). However, his hypoxia progressed; by hospitalization day 2, he required 5 L/min of oxygen delivered by face mask. Remdesivir was discontinued because of gastrointestinal side effects. Laboratory testing revealed a leukocyte count of  $10.1 \times 10^9$  cells/L, a C-reactive protein concentration of 15.0 mg/dL, and a positive COVID-19 PCR test.

Because the patient's hypoxia continued to worsen, we obtained a chest computed tomography scan without IV contrast on hospital day 5. Imaging revealed progressive consolidative opacities bilaterally, most pronounced in the lung bases without a ground glass appearance (Figure 1, panel B). We obtained sputum cultures and started the patient on intravenous piperacillin/tazobactam (3.375 g every 6 h) to treat suspected bacterial pneumonia.

On hospital day 7, sputum Gram stain revealed beaded, gram-positive rods concerning for *Nocardia* spp. (Figure 2, panel A). The patient's antimicrobial treatments were transitioned to intravenous trimethoprim/sulfamethoxazole (TMP/SMX) (5 mg/kg every 8 h) and imipenem (500 mg every 6 h) pending confirmation of suspected *Nocardia* spp. Despite dual therapy, the patient's hypoxia persisted; a repeat chest CT without IV contrast on hospital day 12 showed progression of a consolidative nodular opacity in the left lung base (Figure 1, panel C). Because the patient was not responding to treatment, we added oral linezolid (600 mg every 12 h) to his antimicrobial regimen.

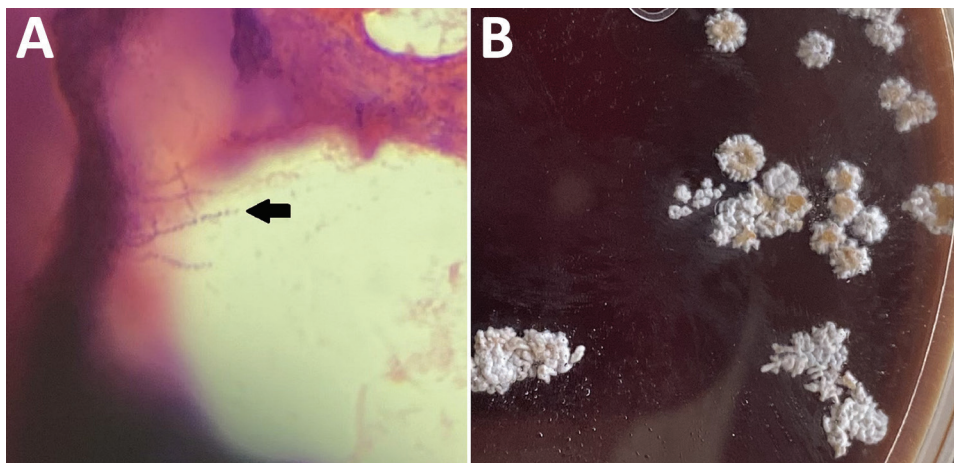
After initiation of linezolid with continued imipenem and TMP/SMX therapy, the patient demonstrated gradual improvement; his hypoxia eventually resolved. On hospital day 16, species identification with matrix-assisted laser desorption/ionization time-of-flight mass spectrometry confirmed *N. pseudobrasiliensis*. Colonies from the *Nocardia* culture plate had the characteristic chalky white appearance and orange pigmentation (Figure 2, panel B). The susceptibility profile (conducted using broth dilution by LabCorp) demonstrated imipenem resistance (Table 1). Because the resistance to imipenem and hyperkalemia was likely caused by TMP/SMX, the patient was discharged on hospital day 20 on linezolid (600 mg 2×/d) and ciprofloxacin (500 mg 2×/d) with plans to continue dual therapy



**Figure 1.** Computed tomography of the chest without contrast showing progression of illness in a 52-year-old immunocompromised man who experienced *Nocardia pseudobrasiliensis* pneumonia after a SARS-CoV-2 infection. A) Scan obtained 4 months before patient sought care. B) Scan on hospitalization day 5 shows development of lung nodules without ground-glass opacities in both lungs. C) Scan on hospitalization day 12 shows progression of nodules on the left lung. D) Scan obtained 28 days after discharge shows improvement of pulmonary nodules.

for  $\geq 6$  weeks after discharge. Of note, a magnetic resonance image of the brain with contrast, which we performed before discharge, did not show ring-enhancing lesions or signs of central nervous system nocardiosis. At the 2-week follow-up visit, the patient's shortness of breath improved and he no longer needed supplemental oxygen at rest but did intermittently require supplemental oxygen on exertion. Imaging at 28 days after discharge showed improvement of the pulmonary nodules (Figure 1, panel D). After a month of outpatient treatment, the patient's symptoms continued to improve, but he experienced a break in therapy for 2 weeks because

of financial constraints, after which the linezolid was switched to TMP/SMX (2 double-strength tablets of 160 mg TMP and 800 SMX every 8 h) and oral ciprofloxacin (500 mg 2 $\times$ /d). After discussion with the patient, we decided to continue dual antimicrobial therapy because of his need to continue taking glucocorticoids for his sarcoidosis. At follow-up 4 months after discharge, the patient reported dyspnea only with heavy exertion and no medication side effects. He would undergo repeat imaging of the chest with plans to transition to TMP/SMX monotherapy if the imaging shows significant improvement of the pulmonary nodules.



**Figure 2.** Histopathology of samples from a 52-year-old immunocompromised man who experienced *Nocardia pseudobrasiliensis* pneumonia after a SARS-CoV-2 infection. A) Branching gram-positive rods (arrow) seen in Gram stain of *Nocardia* culture plate. Original magnification  $\times 100$ . B) *N. pseudobrasiliensis* colonies seen on a *Nocardia* culture plate with characteristic chalky white and orange pigmentation.

**Table 1.** Reported susceptibility of *Nocardia pseudobrasiliensis* bacteria to antimicrobial drugs\*

Antimicrobial drug	This study	Case 1†	Case 2†	Case 3†	Case 4†	Case 5†	Case 6†	Case 7‡
Amikacin	S	R	S	II	S	S	S	VSR or II
Amoxi-clav	R	R	II	S	R	R	R	R
Ceftriaxone	I	R	R	II	S	S	R	VSR or II
Ciprofloxacin	S	S	S	S	S	S	S	II
Clarithromycin	S	S	II	S	S	S	S	S
Doxycycline	R	R	II	II	II	R	R	II
Imipenem	R	R	R	R	II	R	R	VSR or II
Linezolid	S	S	S	II	II	S	S	S
Minocycline	R	R	II	II	M	R	R	II
Moxifloxacin	S	S	II	II	II	S	II	II
Tobramycin	S	II	II	II	II	II	II	II
TMP/SMX	S	R	R	II	S§	R	S	S

\*Amoxi-clav, amoxicillin/clavulanic acid; I, intermediate; II, insufficient information; M, moderate; R, resistant; S, susceptible; TMP/SMX, trimethoprim/sulfamethoxazole; VSR, variable susceptibility results.

†Veerappan Kandasamy et al. (2).

‡Wilson et al. (3).

§This specimen was susceptible to SMX only.

## Discussion

This patient had a previous COVID-19 infection and multiple other risk factors for pulmonary nocardiosis, including diabetes mellitus, bronchiectasis, and immunosuppression caused by sarcoidosis treatment. To date, 10 cases of nocardiosis during or shortly after COVID-19 infection have been reported (Table 2, <https://wwwnc.cdc.gov/EID/article/29/4/22-1439-T2.htm>). All patients had risk factors that predisposed them to infection with *Nocardia* spp. (2–4). Most patients experienced nocardiosis 5–50 days after their SARS-CoV-2 diagnosis; average time to co-infection identification was 17 days. One immunosuppressed patient experienced brain nocardiosis 200 days after their initial COVID-19 diagnosis but had persistently tested positive by reverse transcription PCR for SARS-CoV-2 during that time. Of note, all patients received glucocorticoids during their hospitalizations.

Pulmonary nocardiosis was the most common site of infection, occurring in 7 patients. Central nervous system nocardiosis occurred in 4 patients. Five different species of *Nocardia* were identified, but *N. farcinica* was the most frequently isolated species. This heterogeneity likely explains why each patient was ultimately discharged on a different antimicrobial regimen (Table 2); *Nocardia* species have unique susceptibilities (2,3,14). Our patient's delayed clinical improvement until the addition of linezolid highlights the clinical importance of *Nocardia* species identification and susceptibilities. Ciprofloxacin, clarithromycin, and linezolid are typically effective against *N. pseudobrasiliensis*, whereas TMP/SMX susceptibility varies between cases (Table 1).

The overall risk for all-cause co-infection in patients with COVID-19 appears to be low. A cohort study by Garcia-Vidal et al. (15) analyzed 989 patients admitted to the hospital with COVID-19 and found that only 31 patients had a community-acquired co-

infection at the time of COVID-19 diagnosis; 25/31 patients had bacterial co-infections. Garcia-Vidal et al. also observed 51 total cases of hospital-acquired co-infections diagnosed in 43 patients; 44/51 cases were bacterial co-infections. However, when focusing on COVID-19 patients requiring invasive mechanical ventilation, the incidence of co-infection appears to be higher. Søvik et al. (16) reviewed 156 patients who required mechanical ventilation while infected with COVID-19 and evaluated those patients for co-infection. A total of 67 patients experienced 90 co-infections, 78% of which involved the lower airways; no *Nocardia* spp. infections were reported. Co-infection was strongly associated with dexamethasone use, underlying autoimmune disease, and length of intensive care stay (16). Despite these findings, mechanical ventilation was unlikely to be an independent predisposing factor for pulmonary nocardiosis; 1 patient required mechanical ventilation during their hospitalization.

Analytical epidemiologic studies are needed to assess whether SARS-CoV-2 infection is an independent risk factor for nocardiosis. However, mechanical and immune mechanisms after COVID-19 infection may play a role in *Nocardia* spp. co-infection. Paget and Trottein (17) recently described how influenza virus infection can cause direct or indirect damage to the respiratory barrier, creating conditions for bacterial attachment and translocation, and lead to macrophage, neutrophil, and natural killer cell dysfunction which result in poor bacterial control. COVID-19 infection might promote co-infections by opportunistic pathogens such as *Nocardia* spp. although these mechanisms are not well studied. Because nocardiosis is rarely transmitted in the nosocomial setting (4), the patients identified in this series were likely colonized with *Nocardia* spp. before admission; all of the patients had factors that made them immunocompromised and received steroids before

receiving their *Nocardia* diagnosis (Table 2). It is possible that a COVID-19 infection and the glucocorticoid therapy used to treat it synergistically trigger *Nocardia* spp. co-infection in patients who are already chronically immunocompromised because of the combination of additional immunosuppression and permissive parenchymal conditions. Although a synergistic relationship between COVID-19 and glucocorticoid use is plausible, the data in this study are observational; analytical studies would further clarify the association.

In summary, *Nocardia* bacteria can be a cause of co-infection in patients with COVID-19 pneumonia that may present as further respiratory deterioration. However, *Nocardia* spp. has not been reported in reviews as a cause of co-infection in patients with COVID-19 pneumonia (16,18,19). Immunocompromised patients, such as those on glucocorticoid therapy, those who have received solid organ or hematopoietic cell transplantation, and those positive for HIV, are at higher risk for nocardiosis. Clinicians should include nocardiosis in the differential diagnosis for immunosuppressed patients with severe pneumonia and assess for disseminated disease and central nervous system involvement, especially in the context of potent steroid use to treat immunocompromised patients with COVID-19. Sulfonamide-carbapenem combinations are used as empiric therapy for nocardiosis, but species identification and susceptibility testing are required to select optimal treatment.

### About the Author

Mr. Stamos is a fourth-year medical student at Virginia Commonwealth University. His clinical interests include hematology/oncology, autoimmunity, and opportunistic infections.

### References

- Wallace RJ Jr, Brown BA, Blacklock Z, Ulrich R, Jost K, Brown JM, et al. New *Nocardia* taxon among isolates of *Nocardia brasiliensis* associated with invasive disease. *J Clin Microbiol*. 1995;33:1528-33. <https://doi.org/10.1128/jcm.33.6.1528-1533.1995>
- Veerappan Kandasamy V, Nagabandi A, Horowitz EA, Vivekanandan R. Multidrug-resistant *Nocardia pseudobrasiliensis* presenting as multiple muscle abscesses. *BMJ Case Rep*. 2015;2015:bcr2014205262. <https://doi.org/10.1136/bcr-2014-205262>
- Wilson JW. Nocardiosis: updates and clinical overview. *Mayo Clin Proc*. 2012;87:403-7. <https://doi.org/10.1016/j.mayocp.2011.11.016>
- Saubolle MA, Sussland D. Nocardiosis. *J Clin Microbiol*. 2003;41:4497-501. <https://doi.org/10.1128/JCM.41.10.4497-4501.2003>
- Colaneri M, Lupi M, Sachs M, Ludovisi S, Di Matteo A, Pagnucco L, et al. A challenging case of SARS-CoV-2- AIDS and nocardiosis coinfection from the SMatteo COVID19 Registry (SMACORE). *New Microbiol*. 2021;44:129-34.
- Arif M, Talon A, Sarma H, Munoz J, Charley E. Nocardia after COVID-19 infection. *Chest*. 2021;160(Supplement):A429. <https://doi.org/10.1016/j.chest.2021.07.424>
- Atemnkeng F, Ducey J, Khalil A, Elemam A, Diaz K. Diagnosing disseminated nocardiosis in a patient with COVID-19 pneumonia. *J Med Cases*. 2021;12:319-24. <https://doi.org/10.14740/jmc3716>
- Kaur T, Bhatti W. Complications of high-dose steroids in COVID-19. *Chest*. 2021;160(Supplement):A490. <https://doi.org/10.1016/j.chest.2021.07.480>
- Driscoll S, Carroll WD, Nichani S, Fishwick R, Bakewell K, Gilchrist FJ. COVID-19 infection and nocardiosis causing the death of an adolescent with cystic fibrosis. *Pediatr Pulmonol*. 2022;57:1823-5. <https://doi.org/10.1002/ppul.25954>
- Cicero MN, Memmo AI, Piccionello IR, Seminara G, Benfante A, Scichilone N. A 79-year-old-man with SARS-CoV-2 pneumonia and unusual pulmonary coinfection. *Minerva Respir Med*. 2022;61:86-91. <https://doi.org/10.23736/S2784-8477.21.01993-8>
- Veličković J, Vukičević TA, Spurnić AR, Lazić I, Popović B, Bogdanović I, et al. Case report: nocardial brain abscess in a persistently SARS-CoV-2 PCR positive patient with systemic lupus erythematosus. *Front Med (Lausanne)*. 2022;9:973817. <https://doi.org/10.3389/fmed.2022.973817>
- DiMeglio M, Shaikh H, Newman J, Vazsquez Rubio G. Nocardiosis of the central nervous system: a rare complication of COVID management? *IDCases*. 2022;29:e01599. <https://doi.org/10.1016/j.idcr.2022.e01599>
- Laplace M, Flamand T, Ion C, Gravier S, Mohseni-Zadeh M, Debriel D, et al. Pulmonary nocardiosis as an opportunistic infection in COVID-19. *Eur J Case Rep Intern Med*. 2022;9:003477. [https://doi.org/10.12890/2022\\_003477](https://doi.org/10.12890/2022_003477)
- Toyokawa M, Ohana N, Ueda A, Imai M, Tanno D, Honda M, et al. Identification and antimicrobial susceptibility profiles of *Nocardia* species clinically isolated in Japan. *Sci Rep*. 2021;11:16742. <https://doi.org/10.1038/s41598-021-95870-2>
- García-Vidal C, Sanjuan G, Moreno-García E, Puerta-Alcalde P, García-Pouton N, Chumbita M, et al.; COVID-19 Researchers Group. Incidence of co-infections and superinfections in hospitalized patients with COVID-19: a retrospective cohort study. *Clin Microbiol Infect*. 2021;27:83-8. <https://doi.org/10.1016/j.cmi.2020.07.041>
- Sovik S, Barratt-Due A, Kåsine T, Olasveengen T, Strand MW, Tveita AA, et al. Corticosteroids and superinfections in COVID-19 patients on invasive mechanical ventilation. *J Infect*. 2022;85:57-63. <https://doi.org/10.1016/j.jinf.2022.05.015>
- Paget C, Trottein F. Mechanisms of bacterial superinfection post-influenza: a role for unconventional T cells. *Front Immunol*. 2019;10:336. <https://doi.org/10.3389/fimmu.2019.00336>
- Chong WH, Saha BK, Ramani A, Chopra A. State-of-the-art review of secondary pulmonary infections in patients with COVID-19 pneumonia. *Infection*. 2021;49:591-605. <https://doi.org/10.1007/s15010-021-01602-z>
- Russell CD, Fairfield CJ, Drake TM, Turtle L, Seaton RA, Wootton DG, et al.; ISARIC4C investigators. Co-infections, secondary infections, and antimicrobial use in patients hospitalised with COVID-19 during the first pandemic wave from the ISARIC WHO CCP-UK study: a multicentre, prospective cohort study. *Lancet Microbe*. 2021;2:e354-65. [https://doi.org/10.1016/S2666-5247\(21\)00090-2](https://doi.org/10.1016/S2666-5247(21)00090-2)

Address for correspondence: Jillian E. Raybould, Virginia Commonwealth University Health System, 1200 E Broad St, Richmond, VA 23219, USA; email: jillian.raybould@vcuhealth.org