

such as serologic or molecular methods, are not available in Ecuador, and have been seldom used there, for research purposes (5,8). Moreover, serologic assays have been implemented mostly for other species, such as *P. westermani* and *P. kellicotti* worms (8,9), and clinical validation for *P. mexicanus* worms is lacking (9,10). Limited access to healthcare services in some remote communities can further cause late diagnosis.

Control strategies to limit human infection are hampered by the wide presence of the parasite in many domestic and wild mammals, and the complex life cycle involving 2 intermediate hosts (snail and crustacean) (5). Thus, health education on proper food preparation is the main intervention to reduce infections (1).

Acknowledgments

We thank Alvaro Santiago Guerrero Moscoso, Adela Boboy Porozo, and Joel Adrian Mendoza Alarcon for providing excellent support for screening and management and Teresa Zuppini for organizing drug donation.

This study was partially supported by the Italian Ministry of Health Fondi Ricerca Corrente to Istituto di Ricovero e Cura a Carattere Scientifico Sacro Cuore Don Calabria Hospital, Linea 2.

About the Author

Dr. Diaz is a physician at the Distrito de Salud 08D05 San Lorenzo in San Lorenzo, Ecuador and coordinator of the epidemiology surveillance service of the San Lorenzo Health District. His primary research interests are epidemiology and hygiene.

References

- Diaz JH. Paragonimiasis acquired in the United States: native and nonnative species. *Clin Microbiol Rev.* 2013;26:493–504. <https://doi.org/10.1128/CMR.00103-12>
- Blair D. Lung flukes of the genus *Paragonimus*: ancient and re-emerging pathogens. *Parasitology.* 2022;16:1–36. <https://doi.org/10.1017/S0031182022000300>
- Lane MA, Marcos LA, Onen NF, Demertzis LM, Hayes EV, Davila SZ, et al. *Paragonimus kellicotti* flukes in Missouri, USA. *Emerg Infect Dis.* 2012;18:1263–7. <https://doi.org/10.3201/eid1808.120335>
- Rabone M, Wiethase J, Clark PF, Rollinson D, Cumberlidge N, Emery AM. Endemicity of *Paragonimus* and paragonimiasis in sub-Saharan Africa: a systematic review and mapping reveals stability of transmission in endemic foci for a multi-host parasite system. *PLoS Negl Trop Dis.* 2021;15:e0009120. <https://doi.org/10.1371/journal.pntd.0009120>
- Calvopiña M, Romero D, Castañeda B, Hashiguchi Y, Sugiyama H. Current status of *Paragonimus* and paragonimiasis in Ecuador. *Mem Inst Oswaldo Cruz.* 2014;109:849–55. <https://doi.org/10.1590/0074-0276140042>
- Calvopiña M, Romero-Alvarez D, Macias R, Sugiyama H. Severe pleuropulmonary paragonimiasis caused by *Paragonimus mexicanus* treated as tuberculosis in Ecuador. *Am J Trop Med Hyg.* 2017;96:97–9. <https://doi.org/10.4269/ajtmh.16-0351>
- Lane MA, Barsanti MC, Santos CA, Yeung M, Lubner SJ, Weil GJ. Human paragonimiasis in North America following ingestion of raw crayfish. *Clin Infect Dis.* 2009;49:e55–61. <https://doi.org/10.1086/605534>
- Xunhui Z, Qingming K, Qunbo T, Haojie D, Lesheng Z, Di L, et al. DNA detection of *Paragonimus westermani*: diagnostic validity of a new assay based on loop-mediated isothermal amplification (LAMP) combined with a lateral flow dipstick. *Acta Trop.* 2019;200:105185. <https://doi.org/10.1016/j.actatropica.2019.105185>
- Fischer PU, Weil GJ. North American paragonimiasis: epidemiology and diagnostic strategies. *Expert Rev Anti Infect Ther.* 2015;13:779–86. <https://doi.org/10.1586/14787210.2015.1031745>
- Procop GW. North American paragonimiasis (caused by *Paragonimus kellicotti*) in the context of global paragonimiasis. *Clin Microbiol Rev.* 2009;22:415–46. <https://doi.org/10.1128/CMR.00005-08>

Address for correspondence: Dora Buonfrate, Department of Infectious, Tropical Diseases, and Microbiology, Istituto di Ricovero e Cura a Carattere Scientifico Sacro Cuore Don Calabria Hospital, Via Semprebondi 7, Negrar, Verona 37024 Italy; email: dora.buonfrate@sacrocuore.it

Haematospirillum jordaniae Cellulitis and Bacteremia

Emil Pal, Iztok Štrumbelj, Tjaša Cerar Kišek, Marko Kolenc, Mateja Pirš, Katarina Resman Rus, Tina Triglav, Tatjana Avšič-Županc

Author affiliations: Murska Sobota General Hospital Department of Infectious Diseases, Murska Sobota, Slovenia (E. Pal); National Laboratory of Health, Environment and Food, Murska Sobota (I. Štrumbelj); Institute of Microbiology and Immunology, Ljubljana, Slovenia (T. Cerar Kišek, M. Kolenc, M. Pirš, K. Resman Rus, T. Triglav, T. Avšič-Županc)

DOI: <https://doi.org/10.3201/eid2810.220326>

We isolated *Haematospirillum jordaniae* from a positive blood culture from a 57-year-old man in Slovenia who had bacteremia and bullous cellulitis of lower extremities. The infection was successfully treated with ciprofloxacin. Our findings signal the need for increased awareness about the clinical course of *H. jordaniae* and its potential effects as a human pathogen.

A 57-year-old man living near Lendava, Slovenia, with a medical history of type 2 diabetes, varicose veins in his legs, obesity, and arterial hypertension, sought treatment for a 1-day history of bilateral swelling, redness, warmth, and pain in his lower extremities. The day before, he had pricked himself on his left shin and the sole of his right foot with a reed in the Pacsa Fishing Lake in Hungary. At hospital admission, the patient was febrile (38.5°C) but with vital signs within reference ranges.

Physical examination revealed painful, indurated, erythematous lower extremities, with edema and warmth. Clinically relevant results from blood analysis demonstrated leukocytosis (16.5×10^9 cells/L) with neutrophilia (14.0×10^9 cells/L) and elevated C-reactive protein (CRP; 189 mg/L), suggesting bacterial etiology; procalcitonin (PCT) level was within reference range ($0.1 \mu\text{g/L}$). We empirically introduced therapy with intravenous flucloxacillin (2 g/6 h) for coverage of cellulitis.

On day 2 of hospitalization, extensive bullous changes appeared in the lower extremities. Because of unusual bilateral presentation, we added intravenous therapy with ciprofloxacin. Two days later, fever subsided, and blood leukocyte count returned to

normal (10.5×10^9 cells/L). CRP had mildly increased to 204 mg/L; PCT remained within reference range ($0.4 \mu\text{g/L}$). On day 7 of hospitalization, we observed major improvement in the patient's laboratory parameters (leukocyte count 6.4×10^9 cells/L, CRP 35 mg/L). We continued treatment with intravenous flucloxacillin and ciprofloxacin until discharge on day 13. Signs of bullous cellulitis in the lower extremities had subsided.

Aerobic blood culture bottle was positive after 3 days of incubation. We observed small, slender, pleomorphic bacilli and coccobacilli in Gram stain. After subcultivation onto solid media, we detected growth on blood and chocolate agar (Figure, panels B, C) on the third day, with no growth observed on MacConkey or TCBS (Thiosulfate-citrate-bile salts-sucrose) agar or in microaerophilic atmosphere. However, we could not identify the causative agent using Gram stain from culture (Figure 1, panel A), colony morphology, growth characteristics, or MALDI-TOF (matrix-assisted laser desorption/ionization time-of-flight) mass spectrometry. We suspected *Francisella tularensis* on the basis of clinical manifestations and local epidemiology. We sent blood agar and chocolate agar plates to the reference Biosafety Level 3 laboratory at the Institute of Microbiology and

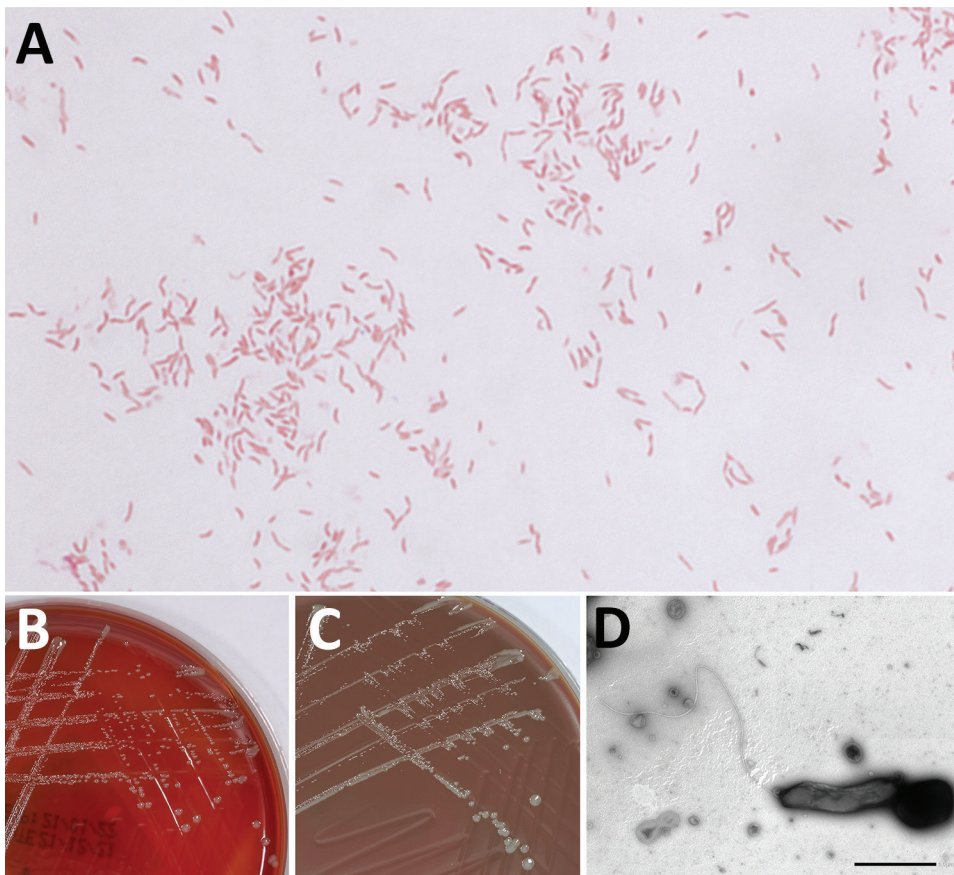


Figure. Detection of *Haematospirillum jordaniae* in a male patient in Slovenia. A) Gram stain of *H. jordaniae*; original magnification $\times 1,000$. B) Colonies on blood agar after 3-day incubation. C) Colonies on chocolate agar after 3-day incubation. D) Transmission electron micrograph image of negatively stained cell of *H. jordaniae* exhibiting flagellum. Scale bar indicates 1 μm .

Table. Antimicrobial susceptibility of *Haematospirillum jordaniae* from a male patient in Slovenia, interpreted according to non-species-related EUCAST PK/PD breakpoints*

| Antimicrobial | MIC, mg/L | Susceptibility category |
|-----------------------------|-----------|-------------------------|
| Benzylpenicillin | 8 | R |
| Ampicillin | 2 | S |
| Amoxicillin/clavulanic acid | 0.125 | S |
| Cefuroxime iv | 16 | R |
| Cefotaxime | 0.25 | S |
| Imipenem | >32 | R |
| Meropenem | 1 | S |
| Ciprofloxacin | <0.002 | S |
| Levofloxacin | <0.002 | S |
| Tigecycline | <0.016 | S |

*EUCAST, <https://www.eucast.org>. PK/PD, pharmacokinetics/pharmacodynamics; R, resistant; S, susceptible

Immunology (Ljubljana, Slovenia) for further analysis. We isolated DNA using QiaAmp DNA Mini Kit (QIAGEN, <https://www.qiagen.com>) and tested it, including dilutions from 1:10 to 1:1,000, by specific real-time PCR, which ruled out *F. tularensis* (1). We performed standard tube extraction protocol for MALDI-TOF mass spectrometry identification using the latest MALDI Biotyper sirius (Bruker Daltonics, <https://www.bruker.com>) and SR library according to manufacturer instructions but could not identify the organism because scores fell below genus cutoff values. We undertook further molecular analyses, included amplifying the 16S V3/V4 region using Mastermix 16S Complete (Molzym, <https://www.molzym.com>). We purified amplicons using QIAquick PCR purification kit (QIAGEN) and sequenced them on a ABI3500 genetic analyzer (Applied Biosystems, <https://www.thermofisher.com>). We analyzed 16S rDNA sequences using the CLC Main Workbench 21.0.5 (QIAGEN) and compared those sequences with others available in the rRNA databases: GenBank BLAST (<https://blast.ncbi.nlm.nih.gov/Blast.cgi>), Ribosomal Database Project (<https://rdp.cme.msu.edu>), and MicrobeNet (<https://microbenet.cdc.gov>). Our isolate most closely matched *Haematospirillum jordaniae* isolate Acr132, H5569 and H2509, with 100% sequence identity. By sequencing a longer, 1,462 bp 16S rRNA region (2), we observed 99.93% identity to *H. jordaniae* H2509 (GenBank accession no. OM075117). After successful molecular identification, we created *H. jordaniae* main spectra profiles according to manufacturer standard procedures and added them to a custom main spectra profile library because the pathogen was not part of any commercial mass spectra library (Appendix Figure, <https://wwwnc.cdc.gov/EID/article/28/10/22-0326-App1.pdf>).

H. jordaniae is a slow-growing, gram-negative rod bacterium that is difficult to identify because it is not included in standard identification databases.

Molecular analysis is necessary for definite identification (3,4). *H. jordaniae*, which belongs to the alphaproteobacteria family *Rhodospirillaceae* (5), was first identified as a potential human pathogen in 2016, when the new genus and species were described from an isolate obtained from a human blood sample in 2010 (3,4). An additional 13 isolates from human blood samples with identical or very similar 16S rRNA sequences, all from men (average age: 60), were later identified at the CDC Special Bacteriology Reference Laboratory (https://www.cdc.gov/ncezid/dhcpp/bacterial_special/special_lab.html).

We determined the antimicrobial susceptibility of *H. jordaniae* using gradient diffusion E-test strips (bioMérieux, <https://www.biomerieux.com>) and Liofilchem MTS (MIC test strips) for amoxicillin/clavulanic acid (<https://www.liofilchem.com>) on Muller-Hinton Fastidious agar (CO₂, 48-h incubation). We interpreted results according to non-species-related EUCAST (<https://www.eucast.org>) PK/PD (pharmacokinetics/pharmacodynamics) antimicrobial susceptibility breakpoints (Table). According to the results of susceptibility testing, fluoroquinolones had the most favorable breakpoint-to-MIC ratios: ciprofloxacin and levofloxacin had MIC <0.002 mg/L (both) and PK/PD breakpoints of 0.25 mg/L (ciprofloxacin) and 0.5 mg/L (levofloxacin).

Molecular evidence of *H. jordaniae* in the blood of any vertebrate other than humans was described only in a bird species, the reed warbler, *Acrocephalus scirpaceus* (6). Possible routes of infection are through environmental contact, mostly following skin injury (4). Current knowledge about *H. jordaniae* is limited; therefore, our findings signal the need for increased awareness about its clinical course and potential effects as a human pathogen.

Acknowledgments

The authors thank our colleagues Meta Kodre, Kitty Žnidar, and Ivana Velimirović for excellent laboratory assistance.

This work was supported by the Slovenian Research Agency (grant P3-0083) and by the network of research infrastructure centers of the University of Ljubljana (MRIC UL, ICBSL3+, grant I0-0510).

About the Author

Dr. Pal works at Murska Sobota General Hospital in Murska Sobota, Slovenia. His research focuses on infectious diseases.

References

1. Versage JL, Severin DDM, Chu MC, Petersen JM. Development of a multitarget real-time TaqMan PCR assay for enhanced detection of *Francisella tularensis* in complex specimens. *J Clin Microbiol*. 2003;41:5492-9. <https://doi.org/10.1128/JCM.41.12.5492-5499.2003>
2. Kawahara M, Rikihisa Y, Lin Q, Isogai E, Tahara K, Itagaki A, et al. Novel genetic variants of *Anaplasma phagocytophilum*, *Anaplasma bovis*, *Anaplasma centrale*, and a novel *Ehrlichia* sp. in wild deer and ticks on two major islands in Japan. *Appl Environ Microbiol*. 2006;72:1102-9. <https://doi.org/10.1128/AEM.72.2.1102-1109.2006>
3. Humrighouse BW, Emery BD, Kelly AJ, Metcalfe MG, Mbizo J, McQuiston JR. *Haematospirillum jordaniae* gen. nov., sp. nov., isolated from human blood samples. *Antonie van Leeuwenhoek*. 2016;109:493-500. <https://doi.org/10.1007/s10482-016-0654-0>
4. Hovan G, Hollinger A. Clinical isolation and identification of *Haematospirillum jordaniae*. *Emerg Infect Dis*. 2018;24:1955-6. <https://doi.org/10.3201/eid2410.180548>
5. Degli Esposti M, Lozano L, Martínez-Romero E. Current phylogeny of Rhodospirillaceae: a multi-approach study. *Mol Phylogenet Evol*. 2019;139:106546. <https://doi.org/10.1016/j.ympev.2019.106546>
6. Hornok S, Ágh N, Takács N, Kontschán J, Hofmann-Lehmann R. *Haematospirillum* and insect Wolbachia DNA in avian blood. *Antonie van Leeuwenhoek*. 2018;111:479-83. <https://doi.org/10.1007/s10482-017-0961-0>

Address for correspondence: Tatjana Avšič-Županc, Institute of Microbiology and Immunology, Faculty of Medicine, Zaloška 4, SI-1000 Ljubljana, Slovenia; email: tatjana.avsic@mf.uni-lj.si

Infection Rate of SARS-CoV-2 in Asymptomatic Healthcare Workers, Sweden, June 2022

Kim Blom, Sebastian Havervall, Ulrika Marking, Nina Greilert Norin, Philip Bacchus, Ramona Groenheit, Andreas Bråve, Charlotte Thålin, Jonas Klingström

Author affiliations: Karolinska Institutet, Stockholm, Sweden (K. Blom, S. Havervall, U. Marking, N. Greilert Norin, C. Thålin, J. Klingström); Public Health Agency of Sweden, Solna, Sweden (K. Blom, R. Groenheit, A. Bråve, J. Klingström); Karolinska Institutet Danderyd Hospital, Stockholm (S. Havervall, U. Marking, N. Greilert Norin, C. Thålin); Swedish Armed Forces, Umeå, Sweden (P. Bacchus)

DOI: <http://doi.org/10.3201/eid2810.221093>

Given the recent surge in SARS-CoV-2 Omicron infections, we performed a quantitative PCR screening survey during June 28–29, 2022, in Stockholm, Sweden, to investigate SARS-CoV-2 point prevalence in a group with high exposure risk. Results showed SARS-CoV-2 infection in 2.3% of healthcare workers who were asymptomatic at time of sampling.

Emerging data show a rapid increase in the prevalence of SARS-CoV-2 infection linked to an increase in COVID-19 cases, which is being driven by the SARS-CoV-2 Omicron variant. Compared with previous variants, Omicron has shown superior capacity for transmission and less sensitivity to neutralizing antibodies induced by vaccination or prior infection with other variants of the virus (1). Initially, the Omicron sublineages BA.1 (including BA.1.1) and BA.2 spread globally at a rapid pace, infecting a large proportion of the population, including vaccinated persons. Nonetheless, vaccines have been shown to provide good protection against severe disease (2). Recently, 2 new sublineages of Omicron, BA.4 and BA.5, have emerged (3). These variants show an even stronger capacity to elude infection- and vaccine-induced immune responses, even evading antibodies in serum from BA.1-infected persons (4,5). Such findings raise concerns that a high community spread might lead to an increasing number of severe cases and a subsequent surge in global hospitalization rates. We performed a quantitative real-time PCR (qPCR) screening survey to estimate the point prevalence of SARS-CoV-2 infection among asymptomatic (defined as having no symptoms at time of sampling) healthcare workers at Danderyd Hospital, Stockholm, Sweden, during June 28–June 29, 2022.

In April and May of 2020, the COMMUNITY study enrolled 2,149 healthcare workers employed at Danderyd Hospital (6). Once enrolled, study participants provided blood samples every 4 months for SARS-CoV-2 serologic assessment (7). Information regarding vaccination status was obtained through the Swedish vaccination register (VAL Vaccinera), and SARS-CoV-2 infection was determined by either seroconversion before vaccination or positive PCR test results obtained from the national communicable diseases register, SmiNet (Public Health Agency of Sweden).

We conducted a qPCR screening survey during June 28–June 29, 2022. We invited all COMMUNITY-study participants who had provided a blood sample in January 2022 (n = 1,412) to participate in the screening survey via a mobile application program. We restricted participation in the survey to