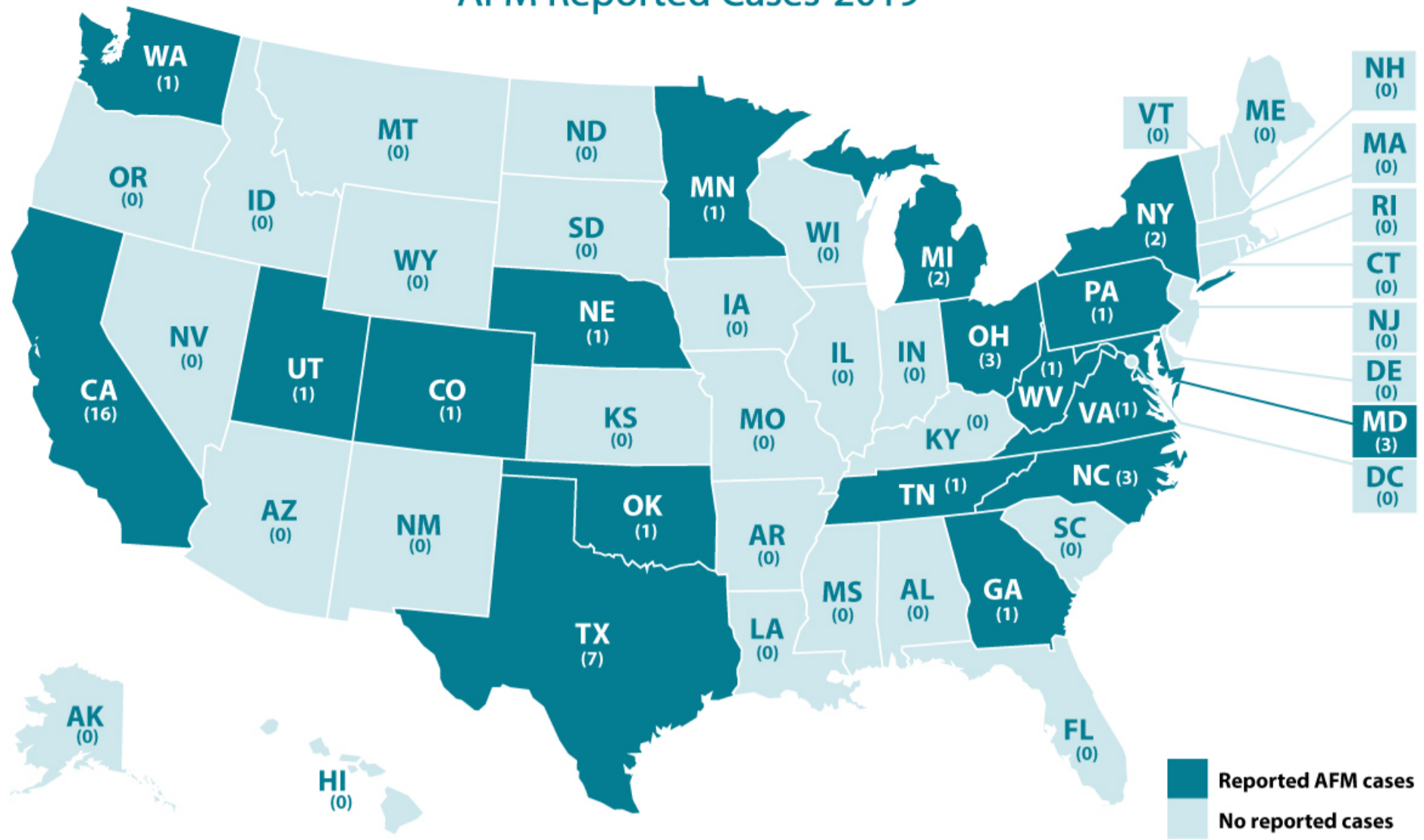






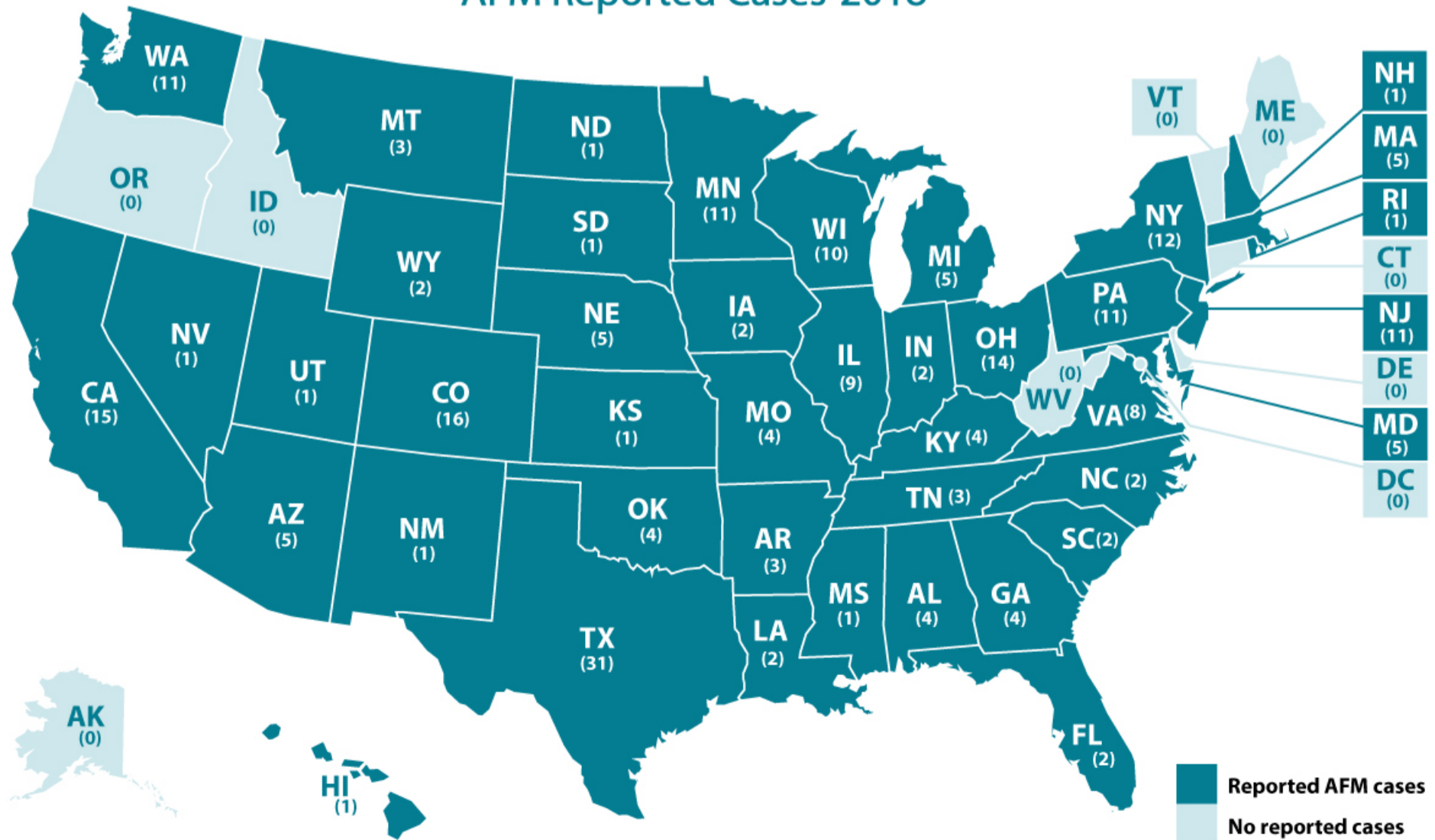
### AFM Reported Cases 2019



In 2019, there were 47 total confirmed cases in 18 states.

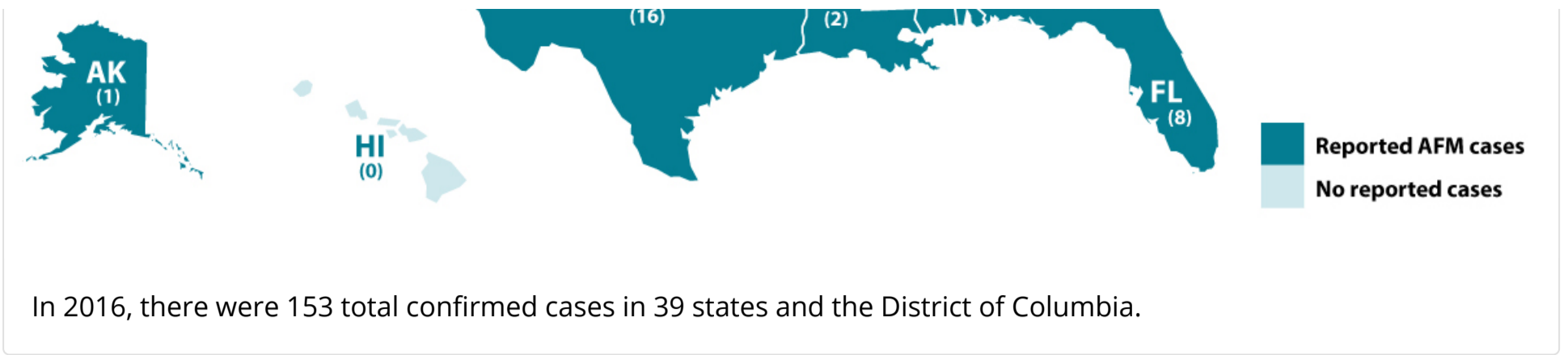
2018

### AFM Reported Cases-2018

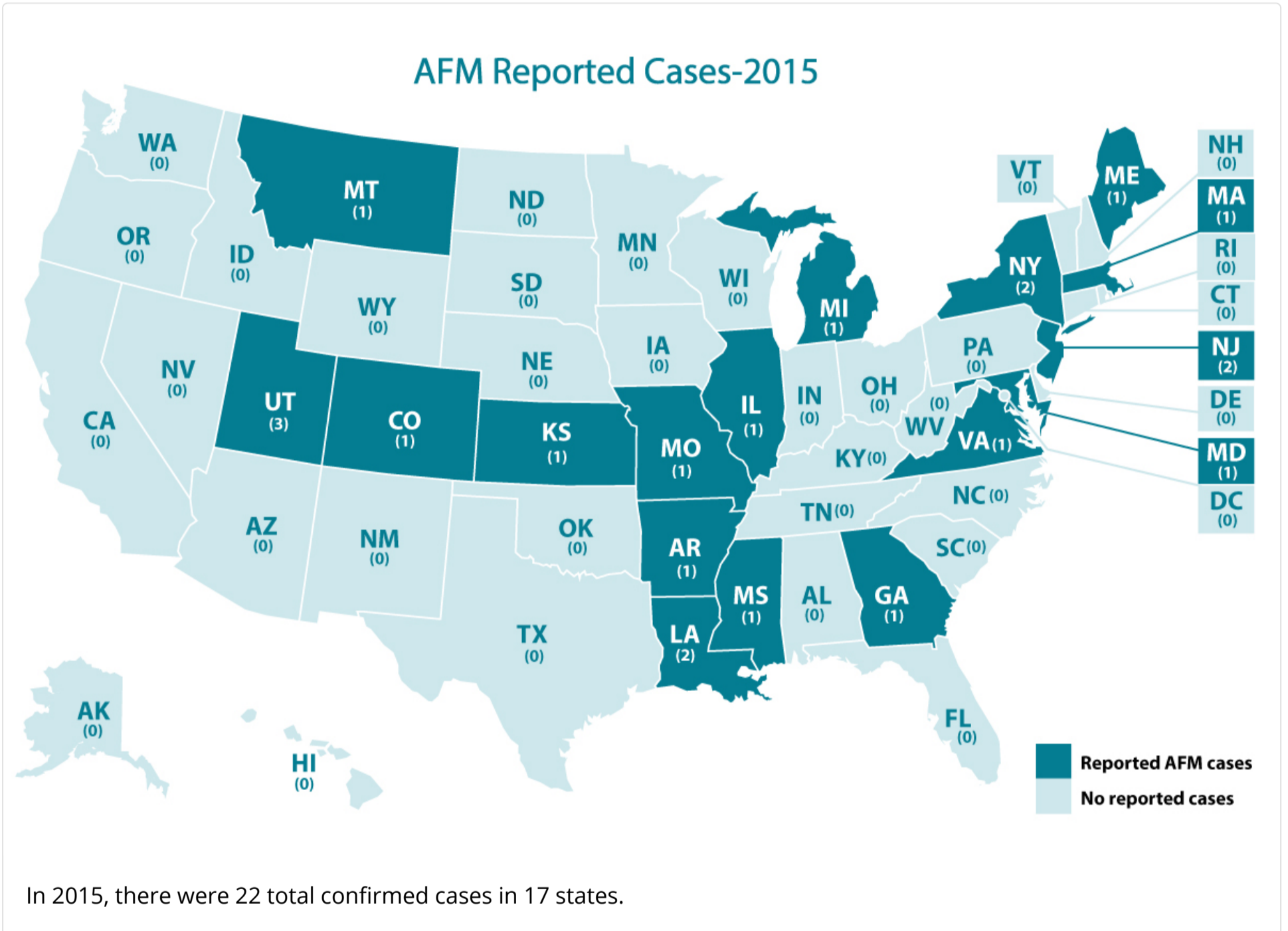


In 2018, there were 238 total confirmed cases in 42 states. One of the confirmed cases is a foreign resident (based

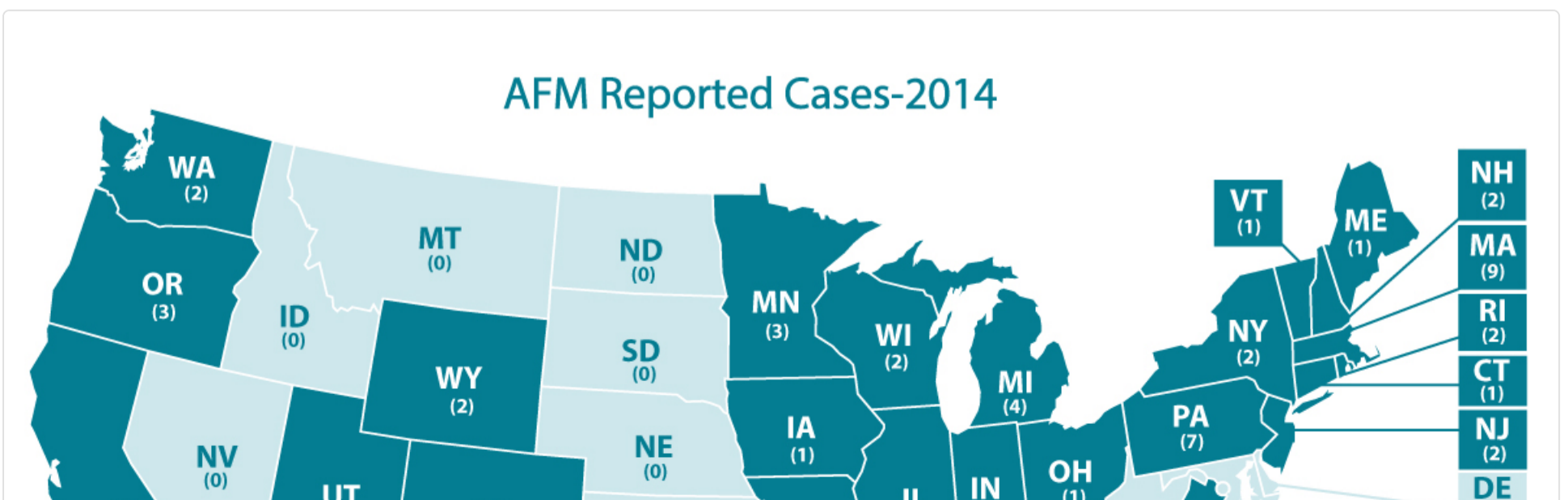


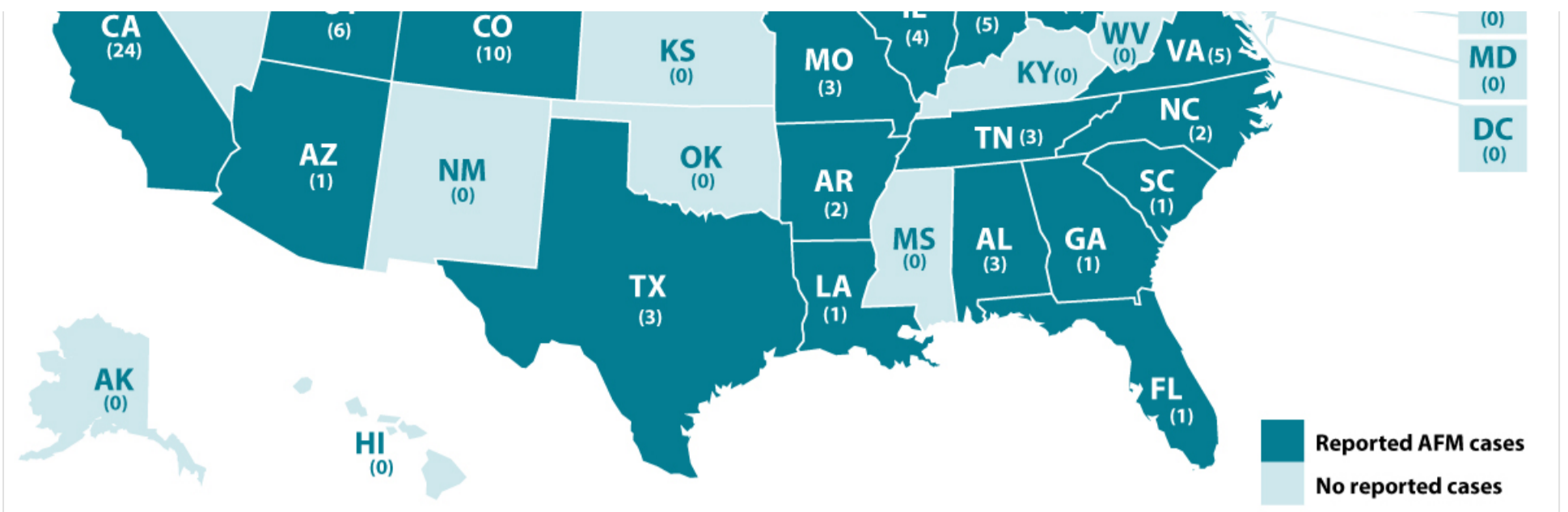


2015



2014





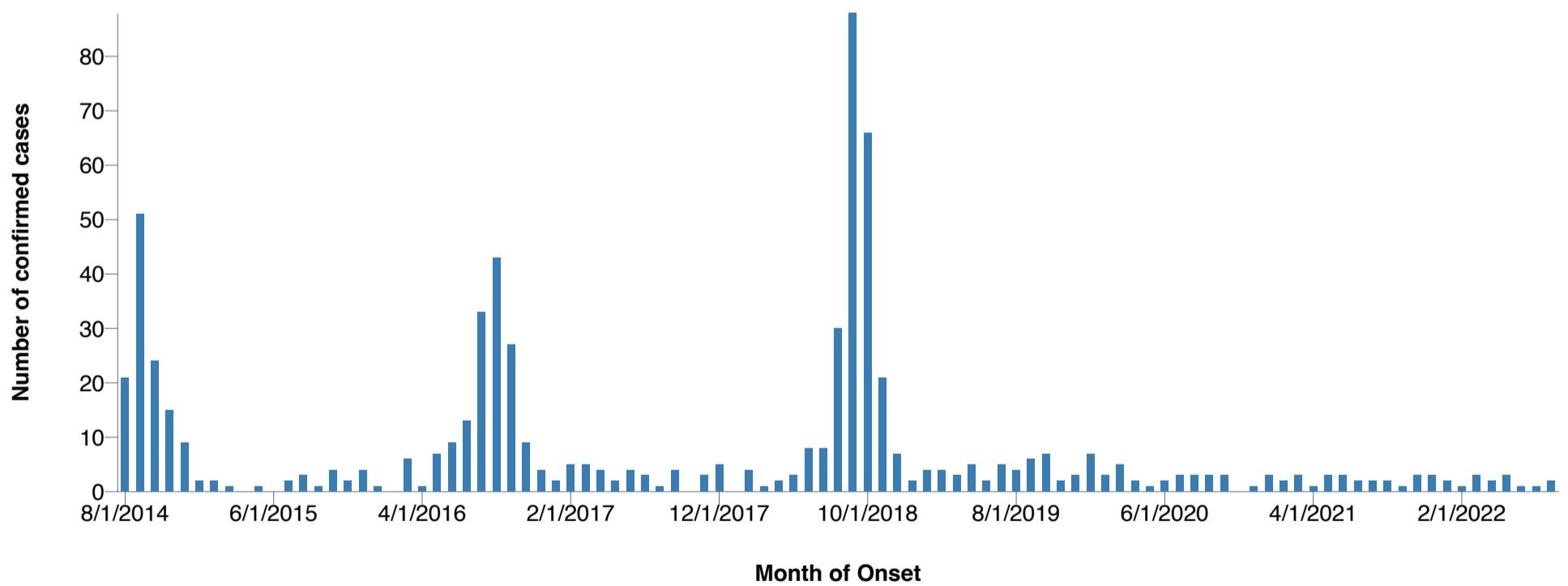
In 2014, there were 120 total confirmed cases in 34 states between the months of August and December. These case counts include only pediatric patients younger than 22 years of age.

We defer to the states to release additional information on cases as they choose.

## Cases by Month, 2014-2022

Most patients developed AFM between August and November, with increases in AFM cases in 2014, 2016, and 2018. Many viruses commonly circulate at this same time of year, including enteroviruses, which are likely responsible for the increase in cases in peak years.

### Confirmed AFM cases by CDC



Data Table				
	8/1/2014	9/1/2014	10/1/2014	11/1/2014
<input type="radio"/> Cases	21	51	24	15

Data table

	Jan	Feb	Mar	Apr	May	Jun	Jul	Aug	Sept	Oct	Nov	Dec	Total
2014	—	—	—	—	—	—	—	21	51	24	15	9	120

	Jan	Feb	Mar	Apr	May	Jun	Jul	Aug	Sept	Oct	Nov	Dec	Total
2015	2	2	1	0	1	0	2	3	1	4	2	4	22
2016	1	0	6	1	7	9	13	33	43	27	9	4	153
2017	2	5	5	4	2	4	3	1	4	0	3	5	38
2018	0	4	1	2	3	8	8	30	88	66	21	7	238
2019	2	4	4	3	5	2	5	4	6	7	2	3	47
2020	7	3	5	2	1	2	3	3	3	3	0	1	33
2021	3	2	3	1	3	3	2	2	2	1	3	3	28
2022	2	1	3	2	3	1	1	2	0	0	0	0	15

Confirmed cases of AFM by month of illness onset. Case Counts are subject to change.

^ Confirmed AFM cases by CDC from August 2014 through September 21, 2022. Case counts are subject to change.

\* The data shown from August 2014 to July 2015 are based on the AFM investigation case definition: onset of acute limb weakness on or after August 1, 2014, and a magnetic resonance image (MRI) showing a spinal cord lesion largely restricted to gray matter in a patient age  $\leq 21$  years.

† The data shown from August 2015 to present are based on the AFM case definition adopted by the Council of State and Territorial Epidemiologists (CSTE): acute onset of focal or flaccid limb weakness and an MRI showing spinal cord lesion largely restricted to gray matter and spanning one or more spinal segments, regardless of age.

For more information, visit the [Case Definitions](#) page.



Case Definitions



About AFM



For Parents of Children with AFM