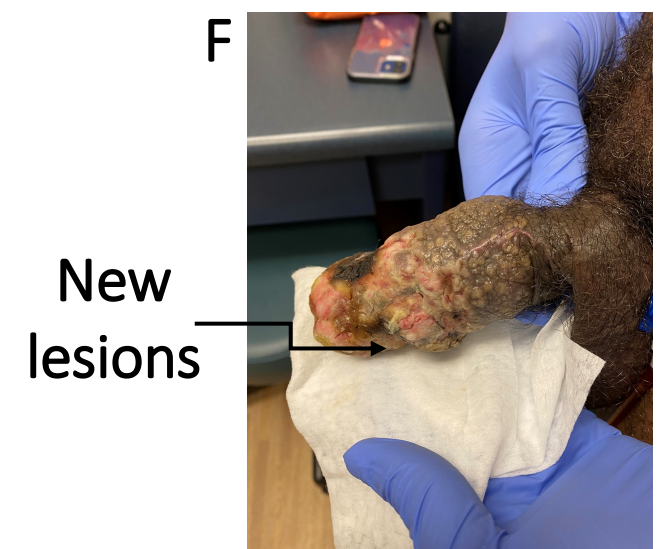
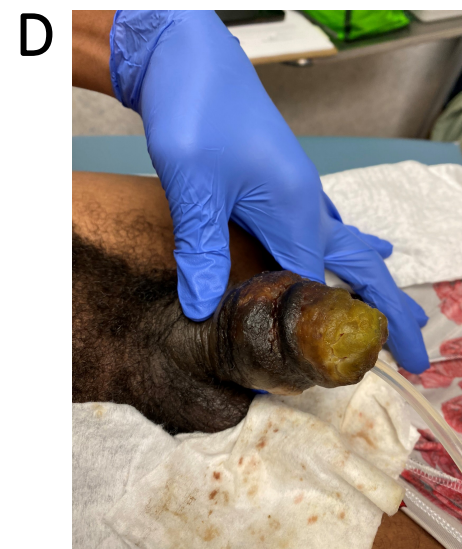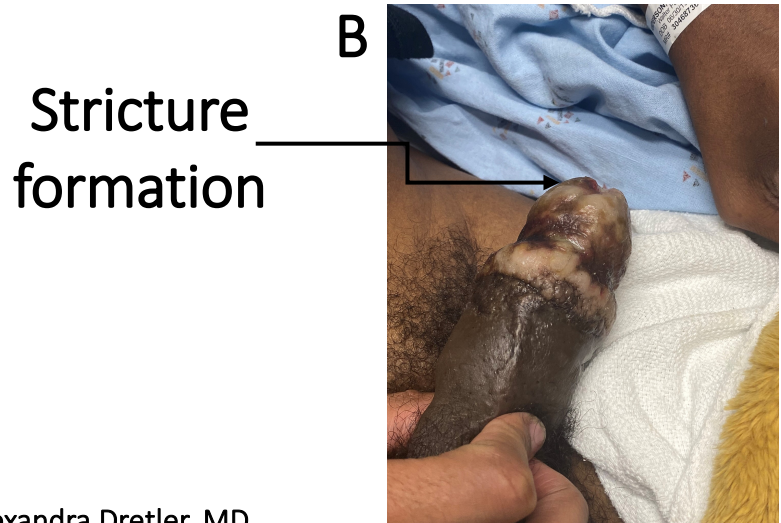
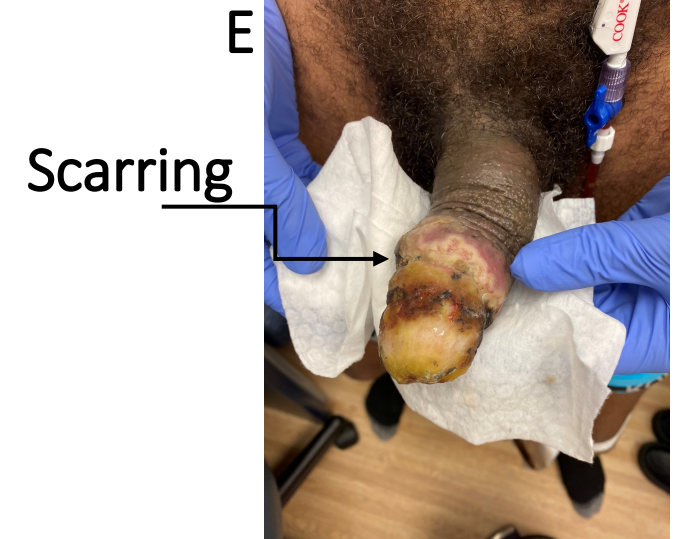
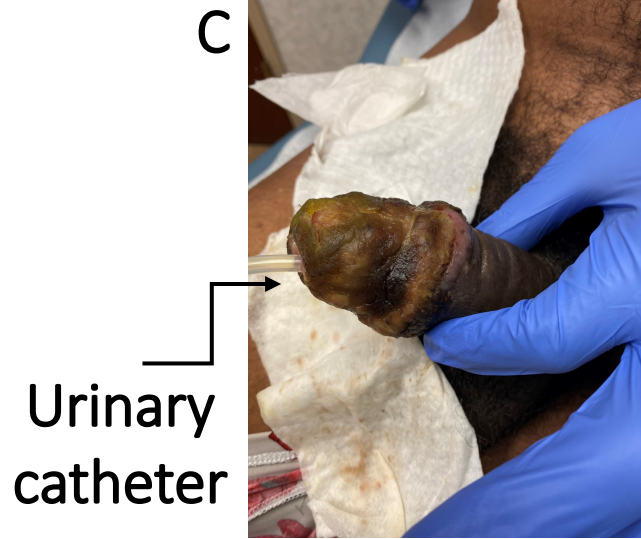

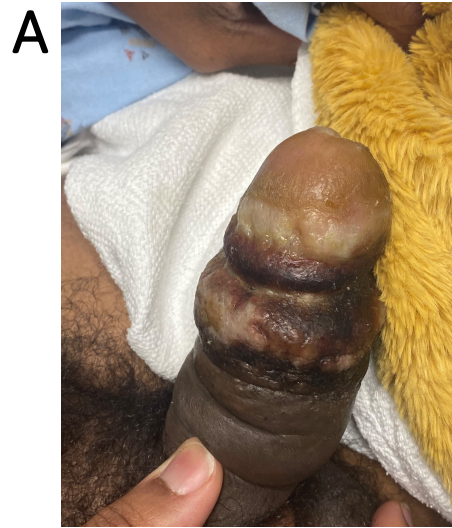
**SUPPLEMENTARY FIGURE 1. Progression of a penile lesion, upon initial evaluation (A, B), after 13 days of tecovirimat (C,D), and at the time of second hospital admission (E,F) in a patient\* with severe monkeypox — United States, August 10–October 10, 2022**



Photos by Alexandra Dretler, MD

\*Patient has consented to the publication of these photographs.