



Clinical Recognition

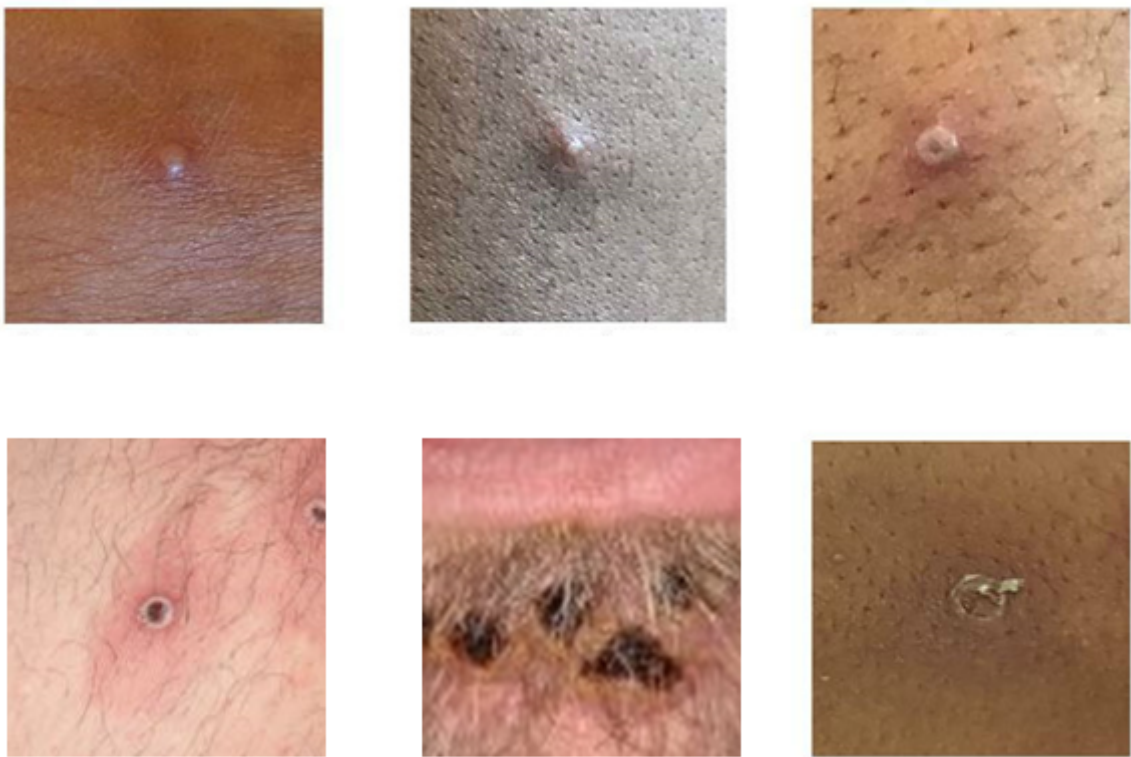Updated August 23, 2022

Key Characteristics for Identifying Monkeypox

- Lesions are firm or rubbery, well-circumscribed, deep-seated, and often develop umbilication (resembles a dot on the top of the lesion).
- During the current global outbreak:
 - Lesions often occur in the genital and anorectal areas or in the mouth.
 - Rash is not always disseminated across many sites on the body.
 - Rash may be confined to only a few lesions or only a single lesion.
 - Rash does not always appear on palms and soles.
- Rectal symptoms (e.g., purulent or bloody stools, rectal pain, or rectal bleeding) have been frequently reported in the current outbreak.
- Lesions are often described as painful until the healing phase when they become itchy (crusts).
- Fever and other prodromal symptoms (e.g., chills, lymphadenopathy, malaise, myalgias, or headache) can occur before rash but may occur after rash or not be present at all.
- Respiratory symptoms (e.g. sore throat, nasal congestion, or cough) can occur.

Examples of Monkeypox Rashes

Photo credit: UK Health Security Agency



Lesions typically develop simultaneously and evolve together on any given part of the body. The evolution of lesions progresses through four stages—macular, papular, vesicular, to pustular—before **scabbing over and desquamation**.

The incubation period is 3-17 days. During this time, a person does not have symptoms and may feel fine.

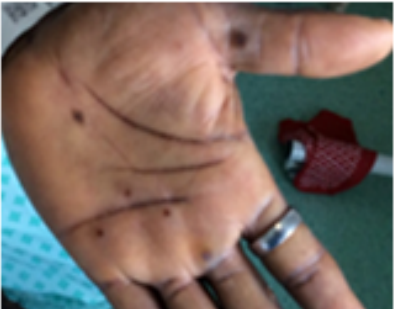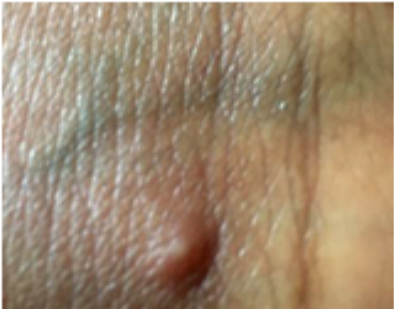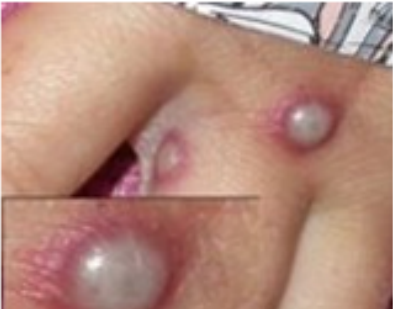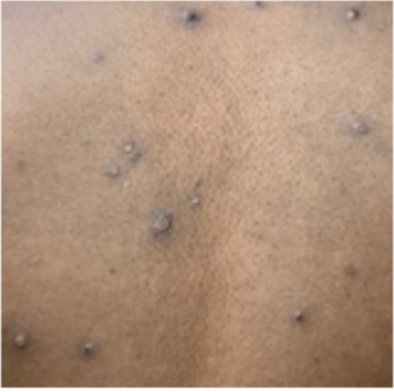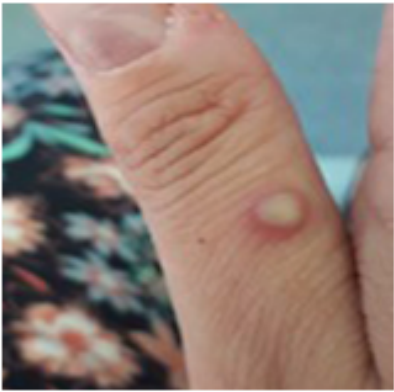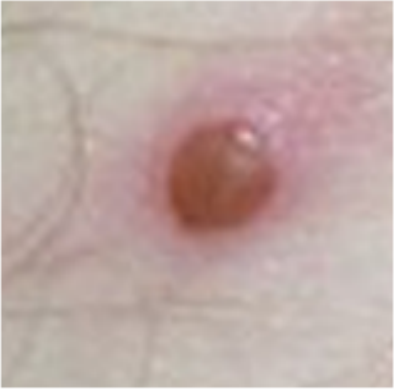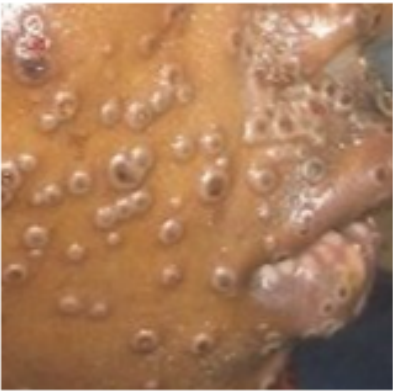The illness typically lasts 2-4 weeks.

The severity of illness can depend upon the initial health of the individual and the route of exposure. The West African virus genetic group, or clade, which is the clade involved in the current outbreak, is associated with milder disease and fewer deaths than the Congo Basin virus clade.


Key Characteristics of Monkeypox Rash

More Monkeypox Rash Photos

Photo Credit: NHS England High Consequence Infectious Diseases Network



Clinical Resources



PRINTOUT
What To Do If You Suspect Monkeypox

File Details: 2 MB, 2 pages

 [View PDF](#)

Enanthem Through the Scab Stage

Stage	Stage Duration	Characteristics
Enanthem		<ul style="list-style-type: none">Sometimes, lesions first form on the tongue and in the mouth.
Macules	1–2 days	<ul style="list-style-type: none">Macular lesions appear.
Papules	1–2 days	<ul style="list-style-type: none">Lesions typically progress from macular (flat) to papular (raised).
Vesicles	1–2 days	<ul style="list-style-type: none">Lesions then typically become vesicular (raised and filled with clear fluid).
Pustules	5–7 days	<ul style="list-style-type: none">Lesions then typically become pustular (filled with opaque fluid) – sharply raised, usually round, and firm to the touch (deep seated).Finally, lesions typically develop a depression in the center (umbilication).The pustules will remain for approximately 5 to 7 days before beginning to crust.
Scabs	7–14 days	<ul style="list-style-type: none">By the end of the second week, pustules have crusted and scabbed over.Scabs will remain for about a week before beginning to fall off.

*This is a typical timeline, but timeline can vary.

Rash resolved

Pitted scars and/or areas of lighter or darker skin may remain after scabs have fallen off. Once all scabs have fallen off and a fresh layer of skin has formed, a person is no longer contagious.

Page last reviewed: August 23, 2022
